

Left ventricular wall rupture following non penetrating trauma to the chest

Narayan Dabas^{1*}, Shankar M Bakkannavar², Vinod C Nayak³, Vikram Palimar⁴

¹Senior Resident, Department of Forensic Medicine and Toxicology, Dr. BSA Hospital, Rohini, New Delhi,

^{2,3}Associate Professor, ⁴Professor, Department of Forensic Medicine and Toxicology, Kasturba Medical College, Manipal University, Manipal, India

***Corresponding author:**

Email: shankar.mb@manipal.edu; drvinay19@gmail.com

ABSTRACT

Non penetrating or closed injury of the chest is one in which the skin and subcutaneous tissues are intact or if pierced course of missile has been such that neither the pleura nor pericardial sac have been injured or these spaces have no direct contact with the outside air. The application of blunt force to chest may result in injuries to the lungs, the heart, the large blood vessels, or the oesophagus. Such injuries may or may not be accompanied by external wounds of the chest wall or fracture of the ribs or the sternum¹ Many-a-times these injuries are overlooked due to the fact that the chest wall made up of rigid structure of ribs will prevent the occurrence of them.

We report a case of haemopericardium secondary to left ventricular wall rupture following non penetrating trauma to the chest without any signs of visible injury over the chest.

Keywords: *Non penetrating trauma; Haemopericardium; Left ventricle rupture.*

INTRODUCTION

Trauma is one of the leading causes of death all over the world. The chest injuries contribute heavily to the increased number of mortality and morbidities due to trauma. Though the vital organs are prevented from externally applied blunt force trauma due to chest wall structure composed of the rigid rib cage, sternum, scapulae and clavicles, approximately 25% deaths are caused by chest or thoracic trauma.^{1,2} Injuries to the chest may be divided into two groups: 1. Penetrating or 'open' chest injuries 2. Non penetrating or 'closed' chest injuries. Penetrating chest injuries can be caused by bullets, knives, skewers or shapened sticks. Wilson defined closed or non-penetrating injury of chest as 'one in which the skin and subcutaneous tissues are intact or if pierced course of missile has been such that neither the pleura nor pericardial sac have been injured or these spaces have no direct contact with the outside air'. The application of blunt force to chest may result in injuries to the lungs, the heart, the large blood vessels, or the oesophagus. Such injuries may or may not be accompanied by external wounds of the chest wall or fracture of the ribs or the sternum³. The forces that cause these injuries may be classified into 7 broad categories: (1) Direct (2) Indirect (3) Bidirectional or Compressive (4) Decelerative (5) Blast (6) Concussive (7) Combined.

Though prevented by rib case and the cushioning effect of lungs the heart can also be affected by non-penetrating thoracic trauma. The ruptured heart is the most common entity of such trauma leading to haemopericardium and cardiac tamponade. Haemopericardium is the pathological

condition found at autopsy and is not quite synonymous with cardiac tamponade, a clinical state caused by progressive collection of blood in the pericardial sac⁴. According to Reddy K S N,⁵ 200 to 300 ml of blood in the pericardial sac can lead to cardiac tamponade. In this paper, we report a case of haemopericardium following blunt trauma in a previously healthy young male.

CASE REPORT

A previously healthy 18 year male was brought dead to the hospital and autopsy was conducted to ascertain the cause and manner of death.

At autopsy on external examination, abrasion reddish measuring 1.3 x 0.2cm was present over right side of the neck. Abraded contusion measuring 2x 2cm was present over the front of neck in midline. Abrasion measuring 2x1.5 cm was present over the back in midline, situated 17 cm above the gluteal cleft.

On internal examination contusion over the chest wall muscles and fracture of ribs were not present. Pericardium was intact and appeared bluish in colour [Fig. 1]. On opening the pericardium, 150 ml of blood was present in the pericardial sac. Rupture of the obtuse marginal branch of circumflex artery with underlying partial thickness laceration measuring 2.5x2.3x0.3 cm was present over lateral wall of the left ventricle, situated 3.5 cm above apex of the heart [Fig. 2]. No hyperemic area was present over the heart surface and all coronary arteries were patent on cut section. Bloodless and flap by flap dissection of neck revealed soft tissues, neck

muscles, vessels, hyoid bone and thyroid cartilage to be intact and unremarkable.

Cause of death was given as complications secondary to rupture of marginal branch of circumflex artery and left ventricular wall.

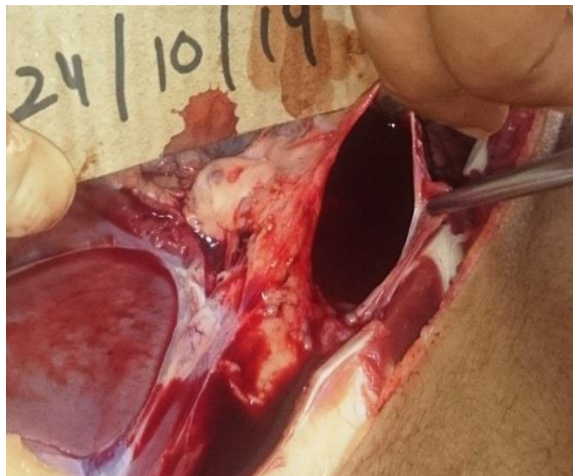


Fig. 1: Blood present in the pericardial sac

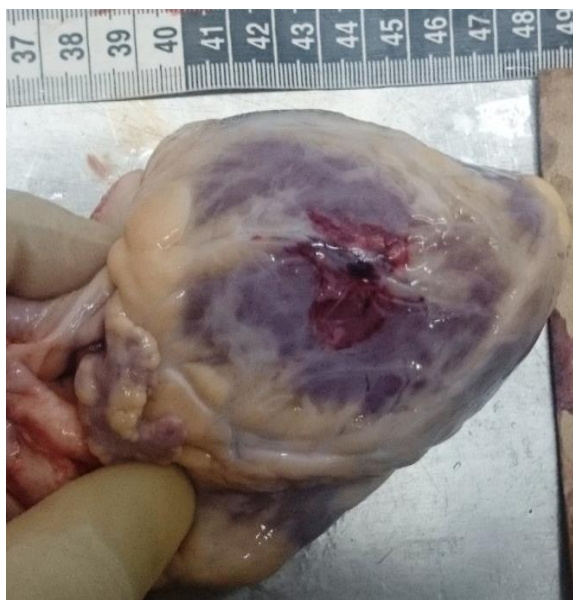

Fig. 2: Partial thickness laceration over lateral wall of the left ventricle.

DISCUSSION

In the present case, external injuries present over the body were not sufficient in ordinary course of nature to cause death. Chest wall muscles, sternum, ribs and mediastinal tissues were intact and unremarkable. Still, the rupture of obtuse marginal branch of circumflex artery and laceration over lateral wall of left ventricle occurred resulting in haemopericardium.

Mechanism leading to cardiac trauma in cases with no evidence of trauma over the chest had been mentioned in past by Parmley L F et al⁶ and

Claude C S et al⁷. Parmley et al⁶ reported 546 cases of non penetrating trauma to the heart, out of which 46 cases had rupture of the left ventricle. According to them, the forces that cause these injuries may be classified into 7 broad categories: (1) Direct (2) Indirect (3) Bidirectional or Compressive (4) Decelerative (5) Blast (6) Concussive (7) Combined.

Claude CS et al⁷ mentioned that, heart lying against the sternum anteriorly and buttressed against the thoracic vertebra posteriorly is vulnerable to compression forces applied to the chest. Wilson JV⁸, any part of the myocardium may be involved, but it would seem that anterior surface of the ventricles was most often affected in young individuals with elastic rib cage.

In our case, the possible mechanism resulting in ventricular wall and vein rupture can be blunt impact over the chest leading to compression of heart between sternum and the thoracic vertebra similar to mechanism described by Claude CS et al⁷ and Wilson JV et al⁸. Indirect forces over abdomen leading to increased tranvascular pressure and cardiac trauma has been mentioned by Beck and Bright⁹, which can be another possible mechanism of haemopericardium as injury was present over back of abdomen in the our case. As the deceased was brought dead to the hospital, and in absence of proper history, it is difficult to comment regarding the probable manner of application of blunt force impact to the chest. In contrast to the anterior surface of left ventricle observed by Wilson JV et al⁸, lateral wall of left ventricle was lacerated in the present case.

Meera TH et al¹⁰ in India found that out of 35 autopsy cases, only 2 cases had cardiac trauma without any external injury of the chest wall, while rest had fracture of either sternum or ribs or both. Out of 2 cases rupture of right atrium was present in one of the case. In contrast to this, site of rupture in our case was left ventricle. Parmley LF et al⁶ in their study found common sites of traumatic cardiac rupture in order of diminishing frequency as right auricle, right ventricle, left ventricle, left auricle, ventricular septum and valves.

Parmley et al⁶ said, the misconception that nonpenetrating trauma to heart is relatively rare, is primarily due to the fact that myocardial contusion or traumatic pericardial lesions are usually well tolerated and the clinical findings are transient and often difficult to recognize. Cardiac trauma in the present case was diagnosed at autopsy which can be due to well tolerated clinical findings by the deceased as mentioned by Parmley LF et al⁶.

In living individuals, blunt trauma to the chest may produce a spectrum of cardiac lesions extending from asymptomatic myocardial contusion to rapidly fatal cardiac rupture. Cardiac trauma other than heart laceration includes contusion of the cardiac conduction system following road traffic accident¹¹.

rupture of coronary artery¹², rupture of cardiac vein¹³ and concussion of heart¹⁴ where biochemical markers like troponin I and T can be useful in diagnosing cardiac injury. Occasionally the syndrome of angina pectoris may follow such cardiac injuries.

Survival following non penetrating traumatic rupture of heart has been reported by DiMarco RF¹⁴, Fukunaga N et al¹³, Leavitt BJ et al¹⁵ and Plooy PD et al¹². Plooy PD et al¹² reported cardiac tamponade following assault with no evidence of rib or sternal fractures. Approximately 300 ml of clotted blood was found in the pericardial sac secondary to 3 cm partial thickness laceration of the left ventricular wall associated with a torn branch of the left anterior descending artery. The laceration was repaired and patient had good postoperative recovery. In our case too, there was partial thickness laceration of left ventricle but there was rupture of marginal branch of left circumflex artery, haemopericardium was diagnosed at autopsy as patient did not receive any treatment and was brought dead to hospital.

Volume of blood in the pericardial sac in our case was 150 ml which was low in comparison to amount of blood mentioned by Reddy KSN⁵. However Swaminathan A et al¹⁶ reviewed deaths due to cardiac tamponade over 10 years in the hospital and reported the range of blood in pericardial sac from 150 ml to 1000 ml.

Keeping into view the possibilities of recovery after operative procedures, mortality in closed chest injury cases/cardiac trauma can be prevented if patient comes to hospital in time. Intoxicating substances or pain due to other injuries can mask symptoms of cardiac trauma. So we recommend physicians to consider cardiac trauma like contusion, laceration, cardiac vein or artery rupture as differential diagnosis in cases of assault, road traffic accidents or fall from height even if there is no evidence of injury to chest.

CONCLUSION

Left ventricular wall rupture along with rupture of obtuse marginal branch of circumflex artery present over the heart surface can occur without any visible trauma to the chest due to compressive forces and can be fatal if not diagnosed in time.

Conflict of Interest: None declared

External funding: None

Ethical approval: As per Institutional ethical committee

REFERENCES:

1. Kent WJ. Thoracic trauma. *Surg Clin N Am* 1980; 60: 957-81.
2. Ziegler DW, Agarwal NN. The morbidity and mortality of rib fractures. *J Trauma* 1994;37:975-9.
3. Gordon I, Shapiro H A. In: *Forensic Medicine A Guide to Principles*; p. 301-03. 2nd ed. Edinburgh London Melbourne and New York. Churchill Livingstone; 1982.
4. Saukko P, Knight B. In: *Knight's Forensic Pathology*; p. 502-03. 3rd ed. London. Arnold; 2004.
5. Reddy KSN. Regional Injuries. *The essentials of Forensic Medicine and Toxicology*; K. Suguna Devi, Hyderabad, 21st Edn. 2002; p. 245-46.
6. Parmley LF, Manion WC and Mattingly TW. Non-penetrating traumatic injury of the heart. *Circulation*, 1958; 18:371-396.
7. Pierucci G, Danesino P. Fluorescent technique for macroscopic detection of electrical metallization. *Z Rechtsmed.* 1981; 86(4): 245-8.
8. Wilson J. V. The pathology of closed injuries of the chest. *Brit. M. J.* 1: 470, 1943.
9. Bright EF, Beck CS. Nonpenetrating wounds of the heart. *Am Heart J.* 1935 10: 293.
10. Meera T. H, Nabachandra H. A postmortem study of blunt cardiac injuries. *JIAFM*, 2005; 27(2): 82-84.
11. Zerbo S., Maresi E. et al. Death of a 23-year-old man from cardiac conduction system injury through a blunt chest impact after a car accident. *Egyptian Journal of Forensic Sciences*, 2014; 4: 137-39.
12. Plooy P D, Popov Y, Klipin M J, Degiannis E. Left ventricular rupture of the heart following assault. *Injury Extra.* 2008; 39: 17-19.
13. Fukunaga N, Konishi Y, Murashita T, Yuzaki M, Shomura Y, Koyama T, Fujiwara H, Okada Y. Survival after simultaneous repair of bichamber cardiac and pulmonary vein rupture caused by blunt chest trauma. *Ann Thorac Surg.* 2012 Jul; 94(1):265-7.
14. DiMarco RF, Layton TR, Manzetti GW, Pellegrini RV. Blunt traumatic rupture of the right atrium and the right superior pulmonary vein. *J Trauma.* 1983 Apr; 23(4):353-5.
15. Leavitt BJ, Meyer JA, Morton JR, Clark DE, Herbert WE, Hiebert CA. Survival following non-penetrating traumatic rupture of cardiac chambers. *Ann Thorac Surg.* Nov 1987; 44(5):532-5.
16. Swaminathan A, Kandaswamy K, Powari M, Mathew J. Dying from cardiac tamponade. *WJES*, 2007; 2:22.