

Silicosis- A Case report

Vibhakar Kumar^{1,*}, A.K. Choudhery², Rani Kumari beck³

¹Assistant Professor, ^{2,3}Tutor, Dept. of Forensic Medicine & Toxicology, MGM Medical College, JSR, Jamshedpur, India

***Corresponding Author:**

Email: vibhakar2000@gmail.com

Abstract

Silicosis is a common occupational lung disease in our country which is caused by the inhalation of crystalline silica dust.⁽⁸⁾ Silica is the most abundant mineral in the mines of Jharkhand. Workers that are involved in constructions, mining, tunnel drilling, sand blasting, pottery industry or glass industry are highest risk of developing this disease. Acute silicosis cases presented with severe symptoms like cough exertional dyspnea, breathlessness, chest pain. In chronic silicosis patient are asymptomatic for several years (10-15 yrs) and simply present with minor RTI symptom. It is usually diagnosed on radiographic (x-ray chest PA View) findings like calcifications of perihilar lymph nodes, diffuse ground glass opacities, large numbers of rounded, solitary nodules or bigger, confluent opacities (Egg cell calcification). Silicosis in combination with Rheumatoid arthritis (caplan syndrome) with rapid development of basilar nodules and mild obstruction of ventilation.⁽¹⁶⁾ Silicosis patient has increase risk of tuberculosis and lung cancer. Once it develops is not curable and only symptomatic treatment can be given. So prevention and control programme for silicosis is beneficial. Acute silicosis having very poor and chronic-poor prognosis.

Keywords: Silica, Silicosis, Egg cell calcification, Mining, Occupational hazards.

Introduction

Among the occupational disease Silicosis is the major cause of permanent disability and mortality in India. It was reported from the kolar gold mines Mysore in 1947, that silicosis is a disease caused by inhaling respirable silica dust. Silica is an abundant mineral that present in the earth's crust. It is found in sand, rock, and mineral ore. The inhalation of dust containing crystalline silica is very harmful to human health and may often be deadly if safety precautions are not used. The person vulnerable for silicosis are who works in mines like gold, copper, silver, nickel, uranium, coal etc. silicates (Talc, kaolin, mica, clays), graphite, slate-quartz, sandstone. Who works in foundry work, stone masons, tunnel drilling, grinding and polishing, sand blasting, pottery industries, glass industries, vitreous enameling, refractory brick manufacturing.⁽¹⁾ Silicosis is usually caused by exposure to silica particles smaller than 5 microns. According to the U.S. National Institute for Occupational Safety and Health (NIOSH), the most important factor in the development of silicosis is "the product of the concentrations of dust containing respirable silica in workplace air and the percentage of respirable silica in the total dust".⁽¹⁵⁾

The respirable silica deposited in lung tissue are act as an antigen and causes inflammation of the lung tissues that ultimately causes fibrosis, the hardening of the lungs, reducing the inspiratory capacity and efficacy of lung.⁽¹⁶⁾ Exposure to crystalline silica also increases the risk of developing tuberculosis and other nonmalignant respiratory diseases. Chronic silicosis,

the most common form of the disease, usually develops after 10 or more years of exposure to relatively low dust

concentrations. Acute silicosis is a rare but highly fatal disease caused by brief but massive exposure to dust with high quartz content.

Material and Methods

In the department of FMT, MGM Medical college Jamshedpur a diagnosed case of Silicosis due to prolong exposure to dust in mines was brought for cause of death –Silicosis which help in compensation.

Results

A 45 year old male brought for autopsy with history of diagnosed case of silicosis under treatment of physician. Physician refused to give Silicosis as a cause of death. So the attendants demand autopsy examination by medical board for cause of death.

The body was very emaciated with loss of subcutaneous fat, abdomen scaphoid, bony prominence present and can be easily counted, Rigor mortis absent, greenish discoloration over abdomen and adjoining lower third chest wall. Right lung (1kg in wt) adherent with chest wall, congested, edematous, fibrosed, nodular, mottled, hard to cut. Left lung (900gm in wt) apical lobe completely necrosed with whorl appearance on section. Lung tissues are send for histopathological examination.

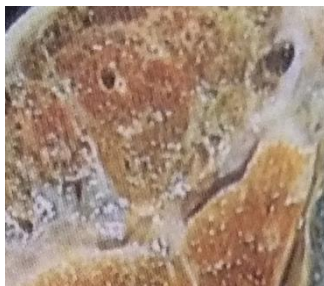

Fig. 1: Macroscopic view of lung

Report

The section shows areas of multiple nodular lesions which have concentric layers of hyalinised collagen surrounded by a dense capsule of more condensed collagens. It also shows the areas of emphysematous changes in lung parenchyma and infiltration with chronic inflammatory cells and fibroblasts.⁽¹³⁾ Histo-pathological features are suggestive of silicosis of lung.

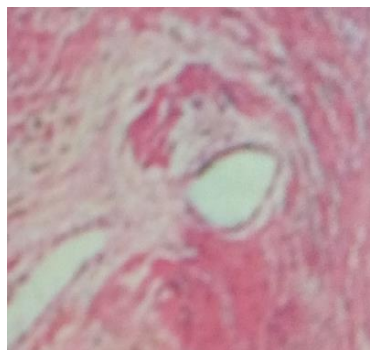


Fig. 2: Several coalescent collagenous silicotic nodules

Discussion

Among the occupational disease Silicosis is the major cause of permanent disability and mortality in India. It was reported from the kolar gold mines Mysore in 1947. In India Industry wise prevalence of silicosis are:- Gold mines (8.84%-13.90%) Mica mines and mica (34%) Manganese mines (4.1%) Lead and zinc mines (30.4%) Stone cutters (20.0%-35.2%) Foundries (27.2%) Ordinances factory (3.5%) Agate workers (38%) Glass bangles workers (7.3%) Slate pencil worker (54.6%) Mica mines and mica processing (5.2%) Quartz crushing (12.0%) Stone quarry (22%) Sand grinding (27.8%) Ceramic and potteries (15.1%).⁽¹⁴⁾ Since chronic silicosis is the most common form of silicosis, generally occurring after decades or more years of exposure, this can give workers a false security, or "it will never happen to me" mentality. While this type of thinking needs to be altered.⁽¹⁵⁾

Despite the data collected on silicosis, the exact incidence of death due to Silicosis is not accurate because the undiagnosed cases of the disease.⁽¹⁷⁾

Today, an effective environmental health and safety (EH&S) professional must make every effort to stay informed about safety and health hazards and their outcomes⁽¹⁸⁾ i.e., Education and demonstration regarding occupational hazards to public who work in such field. It should be the duty of employers that regular medical checkup and safety measure will provided to each and every workers. Silicosis is a non curable disease so prevention and control measures are very important.

Conclusion

Due to negligence of workers, employer and government and delayed appearance of diagnostic features of silicosis it's very difficult to control the disease. It is not a curable disease, so it's better to prevent it either by extension education program for awareness regarding pollution hazards caused by respirable dust of silica. So it's the main tool by which we can decrease the incidence of Silicosis from our society by means of:-

1. Education regarding dust pollution hazards and its morbidity.
2. Use of masks of good quality which control dust particle of less than 5 microns.
3. Wet drilling, proper ventilation with exhaust system.
4. Periodic examination of workers by expert doctors (clinical and lung function test).
5. Registration of workers who exposed in mines/dusty area.
6. Regular inspection by inspectors of pollution control board of government in such factories and mines.
7. Symptomatic treatment like Bronchodilators, oxygen inhalation.
8. Vaccination against pathogens causing respiratory infections (e.g., pneumococci).
9. Anti-tuberculosis treatment (in advanced stage all pt develops tuberculosis).
10. Ventilatory support.
11. Can go for lung transplant in terminal stage.⁽¹¹⁾
12. So in nut shell- it is better to prevent the respirable dust disease rather to treat or control the disease.

References

1. Harrison's Principles of Internal Medicine, Braunwald, Fauci, Longo, Jameson, vol-2, 16th edition; 1523.
2. Oxford Textbook of Medicine; David A. Warrell, Timothy M. Cox, John D. Firth, Edward J. Benz. Jr. Vol-2, Fourth edition; 1474-1475.
3. Cecil Medicine, section-XVI to XXVIII, edited by Arend, Armitage, Clemmons, Drazen, Griggs, Larusso; 23rd edition; Vol-2; 657-658.
4. Kumar and Clark's Clinical medicine edited by Parveen kumar; Michael Clark; eighth edition; 855
5. Respiratory medicine edited by G. John Gibson; Duncan M Geddes; Ulrich costabel; Peter J Sterk; Bryan corrin; Third edition Vol-I; 694-701.

6. Maxcy-Rosenau Last Public health and preventive Medicine; Robert B.Wallace; Neal kohatsu; Brownson; Schecter; Scutchfield; Zaza;15th edition;591-599.
7. Parik^s Textbook of PSM; 19th edit 661.
8. Textbook of Community medicine (P&SM); Sunder lal, Adarsh, Pankaj;4th edition;712.
9. Textbook of PSM, Piyush gupta, Third edition, 704-705.
10. Textbook of Community medicine; second edition; T.Bhasker Rao 401.
11. Mahajan and Gupta Textbook of PSM; Rabindra nath roy; Indranil sinha; Fourth edition; 90
12. Robbins and cortan Pathologic basis of Disease; Kumar; Abbas; Fausto; Aster; Eighth edition; 699
13. ICMR Bulletin 29(9):sp1999.
14. A brief review of silicosis in the united states- NCBI-NIH.
15. Silicosis-Knowledge for medical students and physicians- AMBOSS.
16. Glenn DD. Current issues surrounding silica, professional safety.2008;53(2):37-46.
17. Nash JL. Why are so many exposed. Occupational hazards. 2004;66(11):30-4.
18. Stalnaker C.Hawk^s Nest Tunnel: A forgotten tragedy in safety history. Professional safety.2006;(7):27-33.
19. Reis M. Addressing silicosis head-on stone world.2008;25(2):14-21.