

## Histopathological Examination of Skin in Electrocution Deaths: One Year Autopsy Study

Rekha Narendra Patil<sup>1,\*</sup>, Jayashree Tijare<sup>2</sup>, Waman Raut<sup>3</sup>

<sup>1</sup>Assistant Professor, <sup>2</sup>Associate Professor, <sup>3</sup>Professor & Head, Dept. of Pathology, Government Medical College, Nagpur, India

**\*Corresponding Author:**

Email: rekhapatil3454@yahoo.in

### Abstract

Electrical injuries are essentially accidental. There is significant morbidity and mortality associated with electric injury. Simple safety measures can prevent accidental electrical injuries.

This is an observational retrospective study done in the department of Pathology. This was a one year study. The study year being 2016. Our aim was to study the histomorphology of the skin in electrocution deaths.

The maximum cases of electrocution deaths were due to low voltage (220-240V). This is the voltage supply for the domestic and minor industries. The unique finding of the study was three accidental electrocution deaths by touching the electric farm fence, which are constructed to prevent the entry of wild animals which destroy the crops in the field. Skin is the most frequently involved tissue in electrocution.

We studied skin samples from 29 cases of electrocution deaths. All 29 were accidental deaths. There were 76% males. Upper extremity was the chief area of wounding. The skin samples received showed denudation in 76% cases. The most common histopathological findings were nuclear streaming (96%), dermoepidermal separation (96%) and coagulative necrosis (89%). Electrocution deaths is one of the important cause of negative autopsy.

The histopathological examination of the skin coupled with the circumstantial evidence, proper and complete inspection of the crime site can be very helpful to the forensic surgeon in arriving at the diagnosis of electrocution deaths.

**Keywords:** Electrocution death, Electric burns, Autopsy, Accidental deaths, Skin Histopathology.

### Introduction

In the modern world electricity plays a crucial role in all our day to day activities. Electricity is omnipresent for Domestic and industrial work.<sup>(1-5)</sup>

In the present day world, electricity is required for all domestic and industrial work. So nearly all are exposed to energy agent (electricity) for accomplishing their day to day job.<sup>(1-5)</sup>

Low and high Voltage can cause death due to electrocution. High voltage electrocution deaths are mainly occupational electrocution deaths. Low voltage current (50-1000V AC) supplied to minor industries and domestic use can be responsible for maximum cases of electrocution.<sup>(1,3,6-12)</sup>

Electrocution death (ED) is an unnatural death.<sup>(9)</sup> ED can be described as death owing to passage of electric shock into the body.<sup>(3,4,10)</sup> Electrocution is the chief danger from electricity. Very few people can figure out that very minute amount of electric current is sufficient for electrocution. A small amount of current required to lit a bulb of 7.5W, 120 volt lamp is sufficient to cause death due to electrocution when the current passes through chest. General population have no idea that normal domestic current can be lethal.<sup>(1,3)</sup>

Electrocution is one of the major health problem as it is associated with high morbidity and mortality.<sup>(1,2,4,11)</sup> Electric injury has a wide spectrum.<sup>(10,11)</sup> Brief contact with low voltage intensity can give a transient unpleasant sensation. It can also result in massive injury or even death. Skin lesions, organ damage and death can result

from passage of electric current. They are collectively called as electrocution injury.<sup>(1,3,9-11)</sup>

1<sup>st</sup> case of electric casualty was in France in 1879, when an alternating current (AC) of 250 Volt killed a stage carpenter.<sup>(1,3,5)</sup>

Most of the fatalities due to electrocution are accidental or unintentional. Very few are suicidal and homicidal deaths from electrocution. The important cause for world-wide electrocution are poor maintenance of electric equipments, misuse and carelessness. Lack of knowledge of electrical hazards coupled with lack of safety measures are equally responsible for ED.<sup>(1,3,5,6,9,11)</sup>

Electric mark is the lethal injury caused by the electric current at the site of contact with electricity. It is one of the crucial signs and can be the only evidence of electric injury. The electric marks show a significant variety of gross morphology. When the characteristic findings of electrocution on the body are absent the justification of death due to electrocution is established by excluding the other possible cause of death and supported by the circumstantial evidences collected from the scene of incidence.<sup>(1,5,8,9)</sup>

In such cases the histopathological examination of the skin from the electric mark site can be helpful. In this article we have examined the skin to study the histomorphological changes due to electrocution.

Skin is the most frequently involved tissue in electrocution injuries, but electrocution changes can also be seen in muscles, intra-abdominal organs, bone, neural and orbit.<sup>(9,11,12)</sup>

Medicolegal autopsy (MLA) is done to establish the identity, cause, circumstances, the time of death and help the law enforcing organization to unfold the crime.<sup>(13)</sup>

The primary concern of this article is to examine the histopathological findings in the skin samples received from non-lightening electrocution deaths. These skin changes could be crucial in the MLA to confirm the diagnosis of deaths due to electrocution.

**Material and Methods**

The present study was a one year retrospective observational study carried out at the Pathology department Government Medical College, Nagpur. The study period was 1<sup>st</sup> January 2016 to 31<sup>st</sup> December 2016. Inclusion criteria was all the skin samples from medicolegal autopsies done in cases of non-lightening electrocution deaths. The exclusion criteria was death from any other cause, thermal and lightning electrocution deaths.

The skin samples were examined for gross changes, processed in the routine manner and stained with Haematoxylin and Eosin. The slides were examined to see the histopathological changes.

The data was collected in proper proforma and analysed.

**Observation and Results**

In the year 2016 we received organs from a total of 640 medicolegal autopsies done in our Forensic department and from other nearby districts. We received skin samples from 29 (4.5%) cases of non-lightening electrocution deaths.

The study comprised 29 cases of non-lightening electrocution deaths. There were 22 (76%) males and 7(24%) females. The male to female ratio was 3.1:1.

**Table 1: Showing the age wise distribution of electrocution deaths**

Age group/ (Total number)	No. of Females	No. of Males
0-10 / (1)	0	1
11-20/ (4)	3	1
21-30/ (5)	1	4
31-40/ (8)	1	7
41-50/ (8)	1	7
51-60/ (1)	0	1
61-70/ (2)	1	1
Total / (29)	7	22

The youngest person was a 3 years male and the eldest one was a 70 years female. The majority of the cases i.e., 16 were in the age group of 31 to 50 years. The working adults or bread earners of the family.

All the electrocution deaths (ED) were accidental. There were no suicidal or homicidal deaths in the present study.

**Table 2: Showing the cases according to the manner of electrocution deaths.**

Type of work	Number (%)
Domestic	13 (44.8%)
Job related	10 (34.4%)
Electric Farm fence	3 (10.3%)
Playing	3 (10.3%)

There were 13(44.8%) domestic accidents leading to electrocution deaths. One case was 8 months pregnant lady. She was electrocuted when she was filling water in the cooler. In summer due to the hot weather coolers are used to keep the indoors cool. Such accidents are very common.

There were 10 (34.4%) job related ED. These cases were while doing the electrical repair work, like repairing of electric switches and water pump.

Playing or leisure time activities were the causes of ED in 3 cases. They were in the age group of less than 20 years.

The unique finding was ED due the accidental touch to the electric farm fence. These electric farm fences were constructed for preventing the entry of wild animals, which destroy the crops.

There were 6 ED in wet location and the remaining 23 ED in dry location.

**Table 3: Showing the chief area of wounding**

Body part most affected (Chief area of wounding)	Number
Upper extremity	24 (82.7%)
Lower extremity	3 (10.5%)
Both extremities	2 (6.8%)

The upper extremity was the chief area of wounding in 24 (82.7%) ED. In 3 (10.5%) cases lower extremity was the site of injury. Both extremities were affected in 2 (6.8%) cases.

We received skin samples from the medico legal autopsies done in cases of non-lighting electrocution deaths. The skin samples received were of an average size of 4 to 6cms, with attached subcutaneous tissue.

**Table 4: Gross appearance of the skin**

Gross appearance	Number of cases
Denudation of epidermis with central depression	22 (76%)
No abnormality	5 (17.2%)
Zone of redness	2 (6.8%)

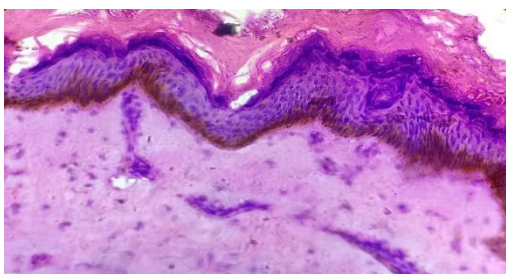
Electric marks in cases of ED show varied gross morphology. In 22(76%) cases of ED there was denudation of epidermis with central depression. In five (17%) cases there was no gross abnormality. In two

(6.8%) cases there was a zone of redness with denudation of epidermis.

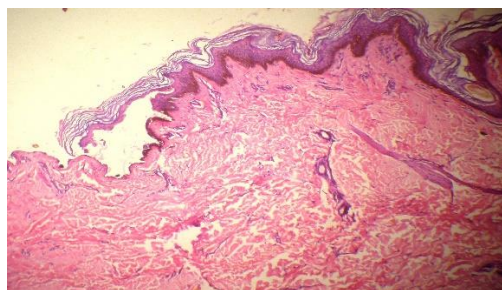
**Table 5: Histopathological findings**

Microscopic finding	Number
Streaming of nuclei	28(96%)
Dermo-epidermal separation	28 (96%)
Coagulative necrosis	26 (89%)
Microblister formation	7 (24%)
Normal skin	1 (3.4%)

The microscopic examination of the skin showed the epidermis dermis with the underlying subcutaneous tissue. The nuclei of epidermis specifically of the basal layer showed elongation and pyknotic appearance. These nuclei were very tightly packed. This change is called as nuclear streaming. (Fig.1) Some of the hair follicles also showed nuclear streaming. Nuclear streaming was seen in 28(96%) cases. The nuclear streaming was marked at the periphery of the lesion. There were few cases in which there was loss of epidermis. (Fig. 2) The epidermis in the preserved site did show nuclear streaming. The other change which was noticed was intraepidermal separation. This was seen as a subcorneal separation.



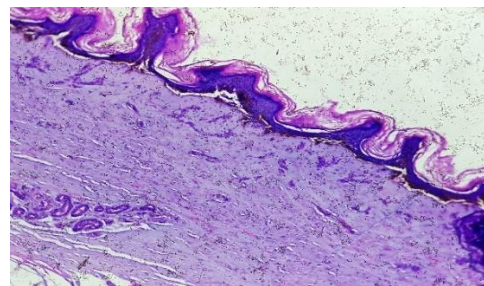
**Fig. 1: Showing nuclear elongation and pyknosis. (Nuclear Streaming)**



**Fig. 2: Scanner view showing partial loss of epidermis. Inset-nucleating streaming**

There was dermoepidermal separation in 28 (96%) cases (Fig. 3). Intraepidermal separation was present in 10 cases. Microblister formation was present in 7 (24%) cases. Coagulative necrosis was bluish appearance of the dermal and underlying tissue. Coagulative necrosis was seen in 26(89%). The dermal and underlying collagen in

section appeared bluish. It is due to the denaturation of collagen. (Fig. 3)



**Fig. 3: Showing the dermo epidermal separation and coagulative necrosis**

Metallization is deposition of the metallic material of the electrode in the tissue. Metallization was not seen in our study.

**Discussion**

Forensic pathology is a subspecialty of pathology that focuses on determining the cause of death by examining a corpse.<sup>(14)</sup> In the present study we examined the histomorphological changes in skin samples received from electrocution deaths (ED).

Diagnosing ED is one of the most crucial role of the forensic science.<sup>(15)</sup>

We received 640 medicolegal autopsy cases in our department. This included 29(4.5%) electrocution deaths.

In other studies ED range was between 1.9% to 3.3%.<sup>(1,2,4)</sup> The present study showed 4.5 % of ED. We receive the MLC samples for doing the histopathological examination of the viscera from medicolegal autopsies done in our college, nearby district hospitals and primary health centres. This can explain the more number of ED in the present study.

In USA approximately 1000 deaths occur every year due to electrocution.<sup>(1,9,11)</sup>

The deaths due to electrocution are mostly accidental. Homicidal and suicidal deaths are few.<sup>(1,4-6,8)</sup> In the present study there were all accidental electrocution deaths as seen in the other studies.<sup>(4,16)</sup>

The present study had a predominance of male patients (76%) comparable with other studies. Males are more exposed to electric menace.<sup>(1,4-6,9,16)</sup>

The chief area of wounding was the upper extremity in 62% cases. Involvement of upper extremity was the most frequent site in other studies.<sup>(1,4,5,8,9,12,16)</sup>

Maximum number of cases 69% were in the age group of 21-50 years. Our study also had 72% cases in the same age group.<sup>(1,4-6,9,12,16)</sup>

Accidental deaths accounted for the majority of ED similar to other studies. In this study all cases were of accidental ED. There were no suicidal or homicidal ED.<sup>(1,2,4-6,8-10,16)</sup>

Maximum accidental electrocution deaths are because of carelessness, use of substandard material. Additional causes include workers lacking the proper knowledge and being unaware of the dangers of working in the unsafe working environment.<sup>(1,4-6,9,12,16)</sup>

The employers and the workers are not adequately trained for the safety measures to be taken while handling the electric equipment's. Both do not realise the significance of the precautionary training and execution of these measures.<sup>(1,9)</sup>

According to the National Electrical Code voltage greater than 600V is considered as a High voltage. Domestic circuits (220/240V) and minor industrial work require Voltage less than 600V. The maximum number of deaths from electrocution occurs with voltage between 110-380V. This is the voltage range for domestic and minor industrial electricity.<sup>(1-3,5,8-10)</sup>

Electric injury happens only when the human body part completes the circuit between the two conductors.<sup>(3)</sup>

The electrocution injuries have a complex pathogenesis and pathophysiology. There is contribution of both thermal and pure electrical damage.<sup>(11,17)</sup>

The amount of electrical injury depends on the various factors like direct or alternating, amperage, voltage, path and duration of current. It also depends on the amount of resistance offered by the tissue and the surface area of body contact.<sup>(3-5,10,16)</sup>

The resistance offered by the tissue to the flow of electric current determines the amount and place of the heat formation. The skin is the human tissue that offers the maximum resistance to the electric current.<sup>(3-5,10)</sup>

The amount of heat produced by electric current is also dependent on the area of contact between the skin and external conductor. If the area is large the heat produced is low to induce burn, but the energy can paralyse respiratory and circulatory functions. If the area is small it can cause burn but the amount is less to cause a significant amount of physiological interference. Electric mark is absent in ED in about 20 to 41 % cases.<sup>(1,5,8,12,16)</sup> In the present study skin samples from 5(17%) cases showed no gross abnormality .

Water lowers the resistance of the skin and electric current density. In the present study we had six ED in the wet location and the skin did not show obvious gross changes in five cases. On microscopic examination these cases showed nuclear streaming in five cases and one case had a normal microscopic appearance. Same findings were also noted by other authors.<sup>(1,4,5,10,16)</sup> Thin and wet skin offers less resistance than thick and dry skin.<sup>(1,4,5,10,16)</sup>

No electrical marks can be found when death occurs in or near moist and water places. This is due to the fact that water lowers the resistance and density of electric current. Similar findings were observed in other studies.<sup>(1,4,5,9,12,16)</sup>

Low voltage skin lesions can be described as well circumscribed small indurated and pale lesions having a depressed grey black area. This is due to coagulative

necrosis of the skin and it is surrounded by small zone of erythema.<sup>(8,15)</sup>

High voltage energy burns cause a lot of heat leading to extensive charring and deep burns.<sup>(3,11,9)</sup>

In the present study are findings were comparable with other studies as shown in the table 6.

**Table 6: Comparison of histopathological findings**

Microscopic finding	Present study cases (%)	Khammam cases (%)	BV 2015 cases (%)
Streaming of nuclei	28(96%)	10(90.90)	6 (100%)
Dermo-epidermal separation	28 (96%)	10(90.90)	6 (100%)
Coagulative necrosis	26 (89%)	10(90.90)	4(66.6%)
Normal skin	1 (3.4%)		-
Microblister formation	10 (32%)	9	-

Histological hall mark of electrocution wound injury is the epidermal nuclear elongation. It is of diagnostic importance.<sup>(15)</sup>

The nuclei of epidermis specially of the basal layer show elongation and pyknotic appearance. These nuclei are very tightly packed. This change is called as nuclear streaming. This is the hall mark of electric injury. At times some of the hair follicles can also show nuclear streaming. The epidermis can be lost due to the injury and so the changes are not visible.

Microblisters are formed by the separation of epidermis and dermis. The spaces formed are result of the gas formed by the cooking of the tissue due to heat.

There is coagulative necrosis of the underlying dermis and subcutaneous tissue. It is due to denaturation of the protein which gives a bluish colour in haematoxylin and eosin stain.

In the present study nuclear streaming, dermoepidermal separation and coagulative necrosis of the underlying tissue was seen in maximum cases. Similar observations were made by other authors.<sup>(5,9,10,16)</sup> Death is mainly due to ventricular fibrillation and respiratory paralysis.<sup>(1,3,10,16)</sup>

On exposure to High voltage current (more than 600V) the skin is ruptured so more current is passed in the body as the resistance is decreased. There is a huge damage to the internal organ with charring.<sup>(3,9,11)</sup>

Risk factors are multiple which include age of the person, wet extremities and underlying heart disease.<sup>(9)</sup>

When an identifiable cause of death is not found after a careful and painstaking autopsy, which includes investigations like the histopathological, biochemical, chemical examination of all relevant internal organs and the meticulous detailing of the circumstantial evidences. These autopsies are called negative autopsies. One of the important causes of the negative autopsy is death due to electrocution.<sup>(10)</sup>

In the early 20<sup>th</sup> century Stefan Jellinck an Austrian scientist did a lot of work on histopathology of electrocution. He challenged the initial belief that microscopic changes of electric injury are due to the burns produced by the heat from electricity. He proved that electric injury leads to specific microscopic changes which are produced by both heat and electric current.<sup>(10,11)</sup>

One of the most important microscopic feature in electric injury is the epidermal nuclear elongation. But some degree of nuclear elongation is seen in the following conditions. They are cauterization injury, blisters due to barbiturate poisoning, blunt dermal trauma and sometimes even in freezing injuries. The electrical injury has the highest intensity of nuclear streaming as compared to other conditions. There are other associated microscopic findings like epidermal and dermal separation, coagulative necrosis helping in arriving at the diagnosis of electrocution death. The proper internal and external examination can help in ruling out the other causes.<sup>(15)</sup>

The histopathological examination of the skin coupled with the circumstantial evidence, proper and complete inspection of the crime site can be very helpful to the forensic surgeon in arriving at the diagnosis of electrocution death.

Sometimes electrical injuries have to be distinguished from thermal burns. The thermal burns can be first, second, third degree burns depending on the depth of tissue destruction. In thermal burns normal epidermis and heat coagulated epidermis is sharply demarcated. The epidermal nuclei are described as pyknotic with perinuclear halo. The hall mark of electrical injury which is nuclear streaming is not described in thermal burns.<sup>(16,18)</sup>

In the diagnosis of electric mark Fourier Transform Infrared (FTIR) spectroscopy can be useful as a complementary tool as demonstrated by Zhang et al.<sup>(15)</sup>

## Conclusion

Electrocution death (ED) constitute a serious health problem with high morbidity and mortality. In cases of death due to electrocution the pathology of trauma is complex. The medicolegal investigations in ED needs greater and mindful detailing.

One of the important causes of negative autopsy is ED. In such cases histopathological examination of skin can be a very diagnostic tool coupled with the circumstantial evidence.

Histopathology of skin in cases of ED can be of great help in arriving at the diagnosis of ED. One of the most important microscopic feature in electric injury is the epidermal nuclear elongation. The other microscopic features are dermo epidermal separation and coagulative necrosis. Our study findings were consistent with other studies.

ED are in many situation accidental and accidents can be prevented by taking proper precautions.

There should be ongoing by-laws and security crusade for decreasing the mishaps from electrocution at domestic and industrial places. Proper supervision at home by the elders when young children use the electric appliances. Instructions should be followed and regular inspection and maintenance should be done by the authorised person.

## References

1. Sachil kumar, Anoop K. Verma, Uma Shankar Singh. Electrocution-related mortality in northern India-A 5 year retrospective study. *Egyptian Journal of Forensic Sciences* 2014;4:1-6.
2. 2.B. D. Gupta, R.A. Mehta, M. M. Trangadia. Profile of Deaths due to Electrocution: A Retrospective Study. *J Indian Acad Forensic Med.*2012;34(1):13-15.
3. A. G. Pathak, N. A. Devraj, K. M. Chaudhari, R. K. Gadhari. Death Due to Fatal Accidental Electrocution: A case report. *Int J Res Med.* 2015;4(1):121-124.
4. Fremingston Marak, Mima Maychet B. Sangma, Ganesh Kumar. Study of electrocution deaths in Puducherry. *International Journal of Forensic Medicine and Toxicological Sciences.*2017;2(1):13-16.
5. Manish Shrigiriwar, Rajesh Bardale, P.G. Dixit. Electrocution: A six year study of Electrical fatalities, *JIAFM* 2007;29(2):50-53.
6. Wick R, Gilbert JD, Simpson E, Byard RW. Fatal electrocution in adults –a 30 year study. *Med Sci Law.*2006;46(2):166-72.
7. Wright RK. Death or injury caused by electrocution. *Clin Lab Med.*1983;3(2):343-53.
8. Ivana Kuhtic, Marija Bakovic, Davor Mayer, Davor Strinovic and Vedrana Petrovecki. Electrical mark in electrocution deaths-A 20 year study. *The open Forensic Science Journal.*2012;5:23-27.
9. Blumenthal R. A retrospective descriptive study of electrocution deaths in Gauteng, South Africa: 2001–2004. *Burns* (2009), doi:10.1016/j.burns.2009.01.009
10. B.Viswakanth and P. Shruthi. Low Voltage Electrocution Deaths and Histopathological Findings: One-Year Prospective Autopsy Study. *Journal of Current Forensic Science Research.* 2015;1:1-5
11. Ashok Surybhanji Gajbhiye, Mona M. Meshram, Rekha S. Gajjaralwar, Amrishi P. Kathod. The Management of Electrical Burn. *Indian J Surg.* 2013;75(4):278–283.
12. Karger B, Suggeler O, Brinkmann B. Electrocution-autopsy study with emphasis on “electrical petechiae”. *Forensic Sci Int.* 2002;126(3):210-13.
13. Lt Col RB Kotabagi, Lt Col SC Charati, Maj D Jayachandar. Clinical Autopsy vs Medicolegal Autopsy. *MJAFI* 2005;61:258-263
14. Minal Chaudhary, Dushyant Bonde, Swati Patil, Madhuri Gawande, Alka Hande and Deepti Jain. Histopathological evaluation of tissue undergoing thermal insult. *J Forensic Dent Sci* 2016;8(2):110.
15. Zhang J, Lin W, Lin H, Wang Z, Dong H. Identification of skin electrical injury using infrared imaging: A possible complementary tool for histological examination. *PLoS One* 12(1):DOI:10.1371/journal.pone.0170844.
16. Guntheti BK, Khaja S, Singh UP. Pattern of injuries due to electric current. *J Indian Acad Forensic Med.* 2012;34(1):44-48.
17. Lee RC. Injury by electrical forces: pathophysiology, manifestations and therapy. *Curr Probl Surg.*1997;34(9):677-764.

18. Hong Wu Heather A. Brandling-Bennett Terence J. Harrist. Noninfectious Vesiculobullous and Vesiculopustular Diseases. David E. Elder, Rosalie Elenitsas, Bernett L. Johnson, George F. Murphy, Xiaowei Xu. Lever's Histopathology of skin. Tenth Edition. USA: Lippincott Williams and Wilkins;2009:274-75.