

Sex determination by post auricular sulcus in South Karnataka

Raju Gouli Mahadevappa¹, Narasimhamurthy Shivalingaiah^{2,*}

¹Vice Principal, Professor & HOD, GIMS, Gadag, Karnataka, ²Associate Professor, Dept. of Forensic Medicine & Toxicology, Basaveshwara Medical College & Hospital, Chitradurga, Karnataka

***Corresponding Author:**

Email: nmurthy31@gmail.com

Abstract

The best reliable method of determining sex from skeletal remains is based on the examination of the hip bone [in nominate / pelvic bone]. However, hip bone specimens may be incomplete or fragmented.

Introduction: The purpose of present study is to identify the best-preserved regions of the hip bone with the greatest diagnostic value for sex determination. Elevation of the auricular surface, and the presence or absence of a post-auricular sulcus can distinguish between male or female.

Materials and Method: The method of visual sex determination uses the unique anatomical feature in hip bone, the efficacy of the methodology is tested on a sample of 250 hip bones of which 25 hip bones are pre-pubertal, 25 pubertal, 150 adults with child bearing age and 50 hip bones are more than 45 year age groups.

Result: The Character of hip bone is found to be typically male or female. It is possible to provide a correct sex diagnosis in 98% of all cases, with an error of 2%.

Conclusion: The post-auricular sulcus is a moderately accurate estimator of sex. Therefore, the purpose of the present study is to test the validity of using auricular surface elevation in infants and the presence or absence of the post-auricular sulcus as astrological indicators of sex in adult skeletal remain.

Keywords: Human hip bone; Forensic anthropology; Sex determination; Human identification

Introduction

Sex determination of the human skeleton is important in bio-archeological and forensic practice. Current opinion reveals that the hip bone as provides the highest accuracy levels for sex determination. However, "simple" observations of the hip bone without any scoring of related traits should be normally considered proper, despite the fact that the results may be surprisingly accurate.⁽¹⁾

There is less frequent damage to the hip bone; sexually dimorphic traits of the posterior pelvis are one of the unique tools to determine sex. Sexually dimorphic traits of the posterior pelvis include the sciatic notch, post-auricular space (space between the posterior Ilium and sacrum) and the Ilium. Especially the dense bone around the sacroiliac joint is less fragile and more likely to survive than the pubic bone.⁽²⁾ Elevation of the auricular surface, and the presence or absence of a post-auricular sulcus can distinguish between male or female.

The traits are evaluated to determine the probability that an individual is male or female. The character of each trait is the most interest to forensic expert faced with sex determining in an individual. These characteristics are generally considered among the most accurate for determining sex from skeletal remains.

In the lights of the Kumho and Daubert standards and the growing independence of the subfield of forensic anthropology, it is imperative that forensic anthropologists empirically test all methods used in medico-legal investigations to determine sex. Non-

metric traits of the pelvis reflecting aspects of reproductive adaptation are usually considered more accurate for determination of sex than metric and non-metric traits are associated with size and shape.

While sexual dimorphism in the sciatic notch and pre-auricular groove has been extensively examined, the elevation of the auricular surface and the post-auricular space has received less scrutiny. The validity of using the elevation of the auricular surface to determine sex in the adult skeleton has only been examined multi-traits and less number of studies is examined the accuracy of the post-auricular sulcus for determination of the sex in adults.⁽³⁾

Materials and Method

The sample includes 250 hip bones ranging from birth to an elder age group and they are categorized into four groups and then visual examination of the hip bones are conducted in JJM Medical College and SSIMS & RC, Davangere, Karnataka, India. Samples which gross fragmented, that would affect the traits were discarded. An effort was made to include a relatively equal number of adult individuals of both sexes from each decade of life. The average age of the sample ranges from birth to more than 45 years for male and female hip bones. The analysis of data has been done by using SPSS software.

Post-auricular sulcus /Interosseous groove: It is located between the iliac tuberosity and post-auricular surface being close to the iliac tuberosity. This groove is formed by the attachment of the Interosseous sacroiliac ligament and superficial portions of both long

and short dorsal sacroiliac ligaments (Andersen)⁽⁴⁾ When present this groove may begin at the vertical [superior] ramus of the auricular surface, continuing along the horizontal [inferior] ramus of the auricular surface and terminate immediately superior to the posterior iliac spine. The post-auricular space is an Interosseous depression dorsally formed between the sacrum and ileum when bone to bone articulation is constructed. This depression is filled by various ligaments including the short and long dorsal sacroiliac ligaments. In case of child bearing age the size of iliac tuberosity is reduced and the auricular surface of the Ilium is elevated. This last process initially results in the formation of the post-auricular sulcus.

Auricular surface changes with age: Perforation of sub-chondral bone of the auricular surface will be generally termed porosity. They are frequently occurring small to large perforations that are to some extent associated with age changes that is microporosity and macroporosity. And most surfaces retain a granular appearance until it is lost to other surface feature. Granulation, however, becomes coarse with increasing age. Thus a fine granular appearance is an indicator of youth, and is usually associated with billowing and striae. Loss of granularity increases with the age, such loss may occur as early as 27years, but in such cases they do not cover the entire surface. Complete loss of granularity may occur as early as the middle of the fourth decade, but does not become a modal condition until about 45-50years, even though many auricular surfaces of this age retain a partially granular appearance.⁽⁵⁾

Observation

In the present study total numbers of 250 hip bones were examined based on age and sex wise, the samples are categorized into four groups pre-pubertal-25 hip bones: 12 -males and 13-females. Pubertal-25 hip bones: 12-males and 13-females. Adults-150 hip bones: 75-males and 75-females. 50-hip bones: 20-males and 30-females of more than 45 years. As shown in the Table 1.

Table 1: Total number of sample [Age group & Sex wise]

Age group	Sample size	Male	Female
Pre pubertal	25	12	13
Pubertal	25	12	13
Adult	150	75	75
>45 year	50	21	29
Total	250	120	130

Sex determination in viable male and female child: hip bones show elevated post auricular surface in

females as shown in the Fig. 1. In case of pre-pubertal hip bone, anatomical structure of post-auricular sulcus in males and females is absent as shown in the Fig. 2. The female pubertal hip bones: post-auricular surface is elevated, but post-auricular sulcus is absent in the female as shown in the Fig. 3. In adult female post-auricular sulcus is prominent, but in case of male hip bones: post-auricular sulcus is absent as shown in the Fig. 4. In the elder female hip bone the post auricular sulcus is less prominent, but porosity and decrease granulocyte seen in auricular surface as pointed in Fig. 5. In adult female post-auricular sulcus is uniformly present, which is more significant. And post-auricular sulcus decreases in the age group of more 45years due to auricular elevation.

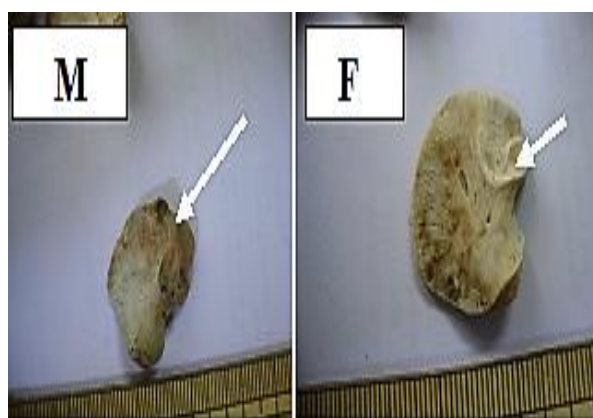


Fig. 1: Sex determination in viable child male and female hip bone: shows post auricular surface elevation in female

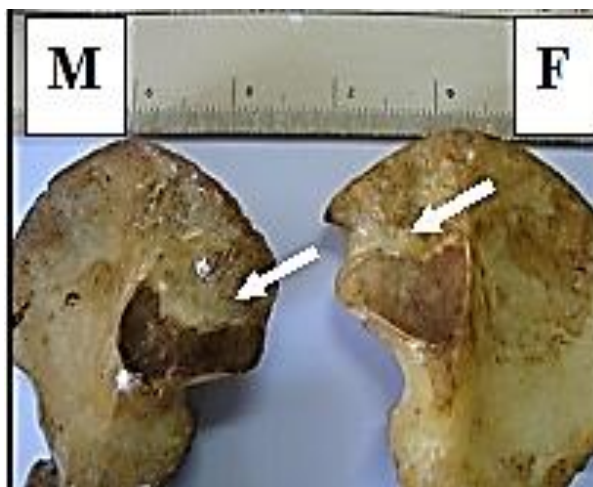


Fig. 2: Sex determinations in pre-pubertal male and female hip bone: shows post-auricular sulcus absent

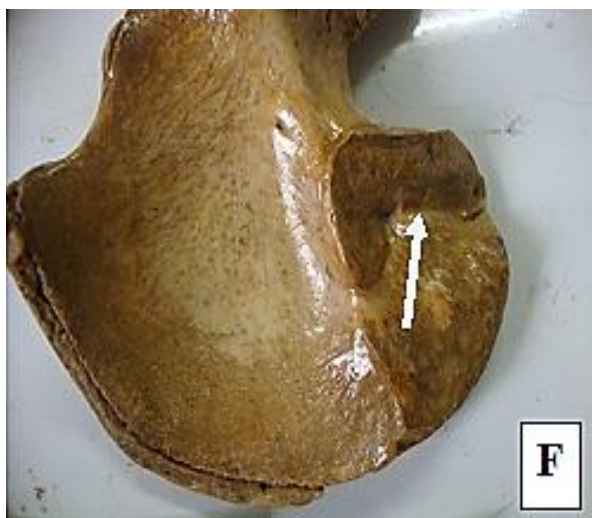

Fig. 3: Sex determinations in pubertal female hip bone: shows auricular surface elevated and post-auricular sulcus absent

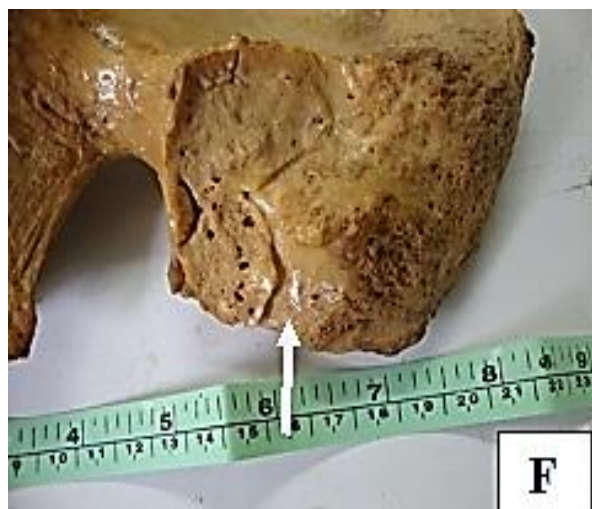

Fig. 5: Sex determinations in elder female hip bone: shows post-auricular sulcus is less prominent with increase porosity and decrease granularity seen at auricular surface

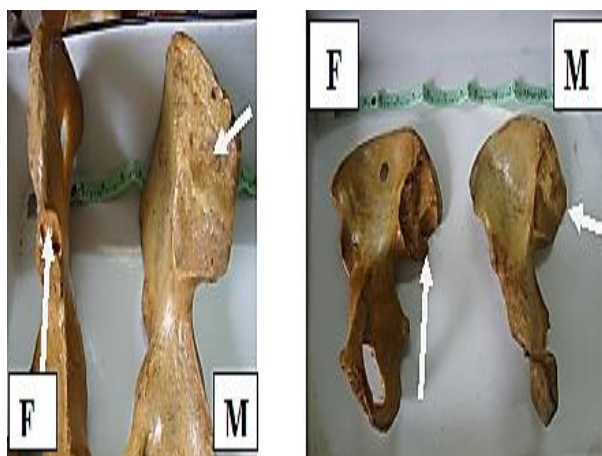


Fig. 4: Sex determinations in adult female hip bone: shows post-auricular sulcus prominent and male hip bone shows post auricular sulcus absent

Present study exhibit prominent post-auricular sulcus, but there is significant independence between the post-auricular sulcus and post-auricular surface expression and sex based on the chi-square test ($p < 0.05$). The presence of a post-auricular sulcus was much more common in adult females (93.3%) than adult males (6.7%) of the individuals. Whereas absent of post-auricular sulcus is 100% in pre-pubertal and pubertal of both sex. (Table 3) In males, the post-auricular sulcus was usually absent, while females frequently exhibit a wide & deep post-auricular sulcus. [Fig. 3] This illustrates typical differences between males and females.

As a result of the sex distribution in adult is determined for 80% of males and 93% of females, (Table 3) with an overall accuracy rate of 83.3% in males, post-auricular sulcus is absent in males but females have 93% and an error rate of 16.7% (Table 2). If the accuracy of the post-auricular sulcus is evaluated in an individual case (assuming an equal chance of the skeleton being male or female), then the probability of being male when the indicator is male (sulcus absent) is 80.0% and the probability of being a female if the indicator is an adult female (sulcus present) is 93.3% Therefore the expected error rate is 0.4% and 0.1% for males and females, respectively. This gives an overall error rate 0.5% for individual cases using post-auricular sulcus.

Table 2: Number of sample & Percentage of Post-auricular sulcus of ileum. [Sex wise]

Post-auricular sulcus in ileum	Male	Percentage	Female	Percentage
Absent	100	83.3	26	16.7
Less prominent	18	15.0	14	19.2
Prominent	2	1.7	90	64.1

Table 3: Number of sample & Percentage of Post-auricular sulcus of ileum. [Age group & Sex wise]

Post-auricular sulcus of ileum	Male Pre-pubertal (%)	M Pubertal (%)	M Adult (%)	M >45 (%)	Female pre-pubertal (%)	F Pubertal (%)	F Adult (%)	F >45 (%)
Absent	12(100%)	12(100%)	60 (80.0%)	16 (76.2%)	13(100%)	10 (76.9%)	01 (1.4%)	02(7.0%)
Less prominent	0	0	14 (18.6%)	04 (19.0%)	00	03 (23.1%)	04 (5.3%)	07(24.1%)
Prominent	0	0	01 (1.4%)	01 (4.8%)	00	00	70 (93.3%)	20(68.9%)

Discussion

Işcan M.Y and Derrick K⁽⁶⁾ developed a visual assessment method to determine sex using the sacroiliac joint, involving the posterior half of the Ilium and its articulation with the sacrum. The structures analyzed included [a] the post-auricular sulcus located between the iliac tuberosity and posterior auricular surface (rarely present in males, commonly present in females) The authors point out that this post-auricular sulcus may disappear with age because of the collapse of the auricular elevation, [b] post-auricular space, formed between the posterior region of the Ilium and the dorsal surface of the sacrum when the two bones are articulated (narrow in males and shallow in females) [c] the iliac tuberosity (round-shaped in males and absent or pointed in females). They found these to be highly accurate in determining sex.

Several researchers have examined the use of auricular surface elevation to determine sex in sub adult skeletons since it; may contribute to the relatively wider hips in females compared to males beginning in infancy.⁽⁷⁾ In many studies the auricular surface was considered elevated only if it was raised along its entire length of both the ventral and dorsal edges. Weaver⁽⁸⁾ found the auricular surface of infants could be used to accurately determination sex in males, but the classification rates were poor for females. Author argued that complete elevation of the auricular surface is rare even among adult females.

Hunt⁽⁹⁾ found the auricular surface to be a poor predictor of sex with infants and young children. The author observed that the prevalence of elevated and non-elevated auricular surfaces changed with age. Then concluded that the auricular surface elevation is not an indicator of sex in sub-adults but rather reflects developmental changes occurring during pre-pubescent develop of Ilium. The present study shows complete elevation of auricular surfaces seen in infancy and adult females.

Mittler and Sheridan⁽¹⁰⁾ study sex differences in the auricular surface of a sample of 58 Nubian sub-adult mummies of known sex (based on preserving external genitalia) ranging in the estimated age from birth to 18 years. The accuracy of the trait at the population level is lower compared to pubic traits. However, adult females are more likely than males to have a sacroiliac

articulation that is elevated from the remainder of the Ilium. When it is present, there is a 99% chance that the individual is female.

Mittler and Sheridan⁽¹⁰⁾ also found similar results in sub adults older than 10 years of age. All of the individuals in their study over the age of 10 years with elevated auricular surfaces were females. They state that “based on a statistical comparison of the sub adult females and males, 10 years of age and older, there is a greater than 99% probability that an individual with an elevated auricular surface is female.” Individuals with a partial or non-elevated auricular surface were classified as male, and only those individuals with completely elevated surfaces were classified as female in the previous studies.

The best methods for determining sex from adult skeletal remains involve measurement and inspection of the hipbone that presents a number of gender related anatomical differences (Ferembach *et al.*⁽¹¹⁾). Numerous sex determination techniques have been proposed based either on examination of specific parts of the hip bone including the pubic bone (Kelley⁽¹²⁾) sacroiliac joint, (Schulter-Ellis *et al.*⁽¹³⁾), hip bone. (Bruzek,⁽¹⁾ Albanese⁽¹⁴⁾) However, a major problem of sex determination in children is that hip bones are often incomplete or damaged. Problems posed by sex determination using fragmented hip bones have been given little attention in the literature. (Işcan, Derrick⁽⁶⁾)

A large sample of hip bones of known sex coming from one modern population is studied morphologically and by multivariate analysis to investigate sexual dimorphism patterns. A principal component analysis of raw data shows that a large amount of the hip bone sexual dimorphism is accounted for by size differences. Variables indicate that the female hip bones are different in traits. The analysis of non-metric traits also shows marked sexual dimorphism in the position of the post-auricular sulcus in females.

Based on the results of Işcan and Derrick's⁽⁶⁾ study, 91% of individuals with a marked post-auricular sulcus were female, suggesting that this is an accurate technique that can be used by forensic anthropologists when analyzing adult skeletal remains. However, the validity of using this method for determining sex does not appear to have been empirically tested except for the extremely small sample used by Işcan and Derrick. Iliac tuberosity was most efficient parameter to identify

male hip bones (90.74%), while post-auricular sulcus was most efficient parameter to identify female hip bones⁽¹⁵⁾ (72.22%).

Present study is very much useful for sex determination of hip bone by post-auricular surface and post-auricular sulcus and it is satisfactorily determined even on a fragment of hip bone since the diagnostic value of feature achieved a success rate greater than 93%. A wide post-auricular surface is the feature that is most common in females. The completely elevated auricular surface, a wide and well defined post-auricular sulcus is almost exclusively found in adult females.

Conclusion

Both elevations of the auricular surface and the expression of the post-auricular sulcus are sexually dimorphic traits of the posterior pelvis that can be used by forensic experts to determine sex, especially when anterior traits are missing or damaged. The problem with the first trait is that not all females have an elevated auricular surface. However, the results of the present study also show that only females had both an elevated auricular surface and a wider post-auricular sulcus. Therefore, the presence of a completely elevated auricular surface, especially if combined with a wider post-auricular sulcus, indicates the human skeleton is female. The absence of these traits provides much less valuable information about gender. But in female children have an elevated auricular surface, can indicate the sex. The presence of a wide and well-marked post-auricular sulcus is a good indicator of adult female sex (98%) and the absence of the sulcus is much less reliable. (2%)

Reference

1. Jaroslav Bruzek. A Method for Visual Determination of Sex, Using the Human Hip Bone. *Am. J. Phys. Anthropol.* 2002;117:157-168.
2. Klepinger LL. *Fundamentals of forensic anthropology.* New York: Wiley-Liss, 2006.
3. Wescott DJ. Sexual dimorphism in auricular surface projection and post-auricular sulcus morphology. *J Forensic Sci.* 2015;60(3):679-85.
4. Andersen, BC. 1986. Parturition scarring as a consequence of flexible pelvic architecture. PhD Thesis, Department of Archaeology, Simon Fraser University, Canada.
5. Lovejoy CO, Meindl RS and et al Chronological metamorphosis of the auricular surface of the Ilium: a new method for the determination of adult skeletal age at death. *Am. J. Phys Anthropol* 1985;68:15-28.
6. Iscan MY, Derrick K, Determination of sex from the sacroiliac joint; a visual assessment technique. *Florida Sci.* 1984; 47:94-98.
7. Reynolds E L. The bony pelvic girdle in early infancy. *Am. J. Phys. Anthropol.* 1945;3:321-54.
8. Weaver DS. Sex differences in the ilia of a known sex and age sample of fetal and infant skeletons. *Am. J. Phys. Anthropol.* 1980;52:191-95.
9. Hunt DR. Sex determination in the sub-adult ilia: an indirect test of Weaver's non-metric sexing method. *J. Of Forensic Sci.* 1990;35:881-85.
10. Mittler DM, Sheridan SG. Sex determination in the sub-adult using auricular surface morphology: a forensic science perspective. *J of Forensic Sci.* 1992; 37:1068-075.
11. Ferembach D, Schwidetzky I & Stloukal M. Recommendations for age and sex diagnoses of skeletons. *J Hum.Evol.* 1980;9:517-549.
12. Kelley MA. Sex determination with fragmented skeletal remains. *J. of Forensic Sci.* 1979;24(1):154-58.
13. Schuller Ellis FP, Schmid DJ & et al. Determination of sex with a discriminant analysis of new pelvic bone measurements: part II. *J. of Forensic Sci.* 1985;30(1):178-85.
14. Albanese J. A metric method for sex determination using the hip bone and the femur. *J. of Forensic Sci.* 2003;2:263-73.
15. Gohil DV, Dangar KP, Rathod SP and et al. A study of morphological features of Ilium for sex determination in Gujarat state *J of Research in Medical and Dental Sci.* 2014;2(4):75-78.