

Terson's Syndrome: a frequently missed ophthalmologic finding in subarachnoid hemorrhage

Suraj Sundaragiri^{1*}, Vijayadurga Koppada²

¹Senior Resident, Dept. of Forensic Medicine & Toxicology, Jawaharlal Institute of Postgraduate Medical Education & Research, Puducherry, ²Tutor, Dept. of Forensic Medicine & Toxicology, ESIC Medical College, Sanathnagar, Hyderabad, Telangana

***Corresponding Author:**

Email: drsurajfm@gmail.com

Abstract

Terson's syndrome is vitreous hemorrhage occurring consequent to subarachnoid hemorrhage. We present here the case of 60 years old male person who met with road traffic accident. He was transported to a hospital where diffuse subarachnoid hemorrhage was diagnosed radiologically. But before further studies could be Pursued, and surgical intervention started, his condition deteriorated and he died. The autopsy demonstrated diffuse subarachnoid hemorrhage of the brain with bilateral vitreous hemorrhage. Terson's syndrome is certainly an indicator of increased risk of mortality without early surgical attention. This paper reports here radiological and autopsy findings of such case and recommends further studies to estimate of the frequency of vitreous hemorrhage in patients with subarachnoid hemorrhage, and to compare its mortality in patients with and without vitreous hemorrhage. It also recommends the forensic pathologists to assess the vitreous hemorrhage in all cases of subarachnoid hemorrhage with aneurysmal or traumatic brain injury.

Keywords: Terson's syndrome, Vitreous hemorrhage, Subarachnoid hemorrhage, Trauma, Mortality.

Access this article online	
Quick Response Code:	Website: www.innovativepublication.com
	DOI: 10.5958/2394-6776.2016.00034.5

Introduction

Intraocular hemorrhages can be sub-retinal, retinal, subhyaloidal or intra-vitreous.⁽¹⁾ Its likely cause is a rapid rise in intracranial pressure. In 1881, Moritz Litten, German ophthalmologist first described a retinal hemorrhage associated with subarachnoid hemorrhage.⁽²⁾ The syndrome of vitreous hemorrhage in association with subarachnoid haemorrhage (SAH) was first described by Albert Terson, French ophthalmologist in 1900.⁽²⁾ Since then, Terson's syndrome has been defined as retinal or vitreous hemorrhage in the presence of intracranial hemorrhage mostly SAH, occurring in 12.5% to 40% of cases.^[1,3-6] In SAH, 13% of patients have Terson's syndrome, in association with diffuse SAH, and significant increase of risk of death.⁽²⁾ Reported complications of Terson's syndrome include visual loss,⁽²⁾ macular holes,⁽⁷⁾ epiretinal membrane formation,^(8,9) retinal folds,^(9,10) proliferative vitreoretinopathy,^(11,12) and retinal Detachment.⁽¹²⁾

The pathogenesis of vitreous hemorrhage arising of various conditions has been much debated.⁽¹³⁻¹⁶⁾ It is believed that intracranial aneurysmal rupture or head trauma rapidly rises the intracranial pressure.^(1,5) This sudden rise in intracranial pressure may force blood into the subarachnoid space along the optic nerve sheath into

the preretinal space, or may lead to decrease in venous return to the cavernous sinus or obstruct the central retinal vein and retinochoroidal anastomoses, culminating in venous stasis and hemorrhage, i.e. causing distension and rupture of peripapillary and retinal capillaries resulting in remarkable hemorrhage in the vitreous cavity or subhyaloid space.^(2,14-17) Clinical examination and pathological studies of the ocular hemorrhages in Terson's syndrome have revealed a dome-shaped posterior pole membrane arising in the subhyaloid space,^(18,19) where the blood may remain confined appearing as a heap on the retina, or may decompress partially or completely through the hyaloid membrane and seep into vitreous.⁽²³⁾ We postulate that the crescents or mounds seen in our imaging study represents the subhyaloid blood.

Case Report

A case of 60 years old male person who met with road traffic accident was transported to a hospital. Axial Non- Contrast Computerized Tomography(CT) scan revealed left temporal bone fracture, left frontal temporal and parietal subdural hemorrhage and diffuse subarachnoid hemorrhage, and bilateral subhyaloid and vitreous hemorrhage. (**Fig. 1**) before further studies could be pursued, and surgical intervention started, his condition worsened and he died. On Examination at autopsy, eyes was closed, conjunctiva pale, cornea hazy, pupils dilated was noted. Bilateral vitreous hemorrhage was assessed (**Fig. 2**) and the vitreous humor was replaced with saline for cosmetic reasons. Postmortem examination revealed sub scalp contusion and pericranial hemorrhage over both parieto-occipital and left temporal area of scalp with contusion of left

temporalis muscle. Fissure fracture measuring 16 cm was present extending from left squamous temporal bone to external occipital protuberance. On opening of the skull, diffuse bilateral subdural hemorrhage and subarachnoid haemorrhage (Fig. 3) was noted over both cerebral hemispheres, and cerebellum. Contusion of size

measuring 6 cm x 4 cm is present over base of both frontal lobes. Contusion of size measuring 7cm x 4cm over lateral aspect of left temporal lobe. The brain was preserved and examined post fixation to rule out any aneurysms. No aneurysmal bleeds was detected on serial coronal sections.

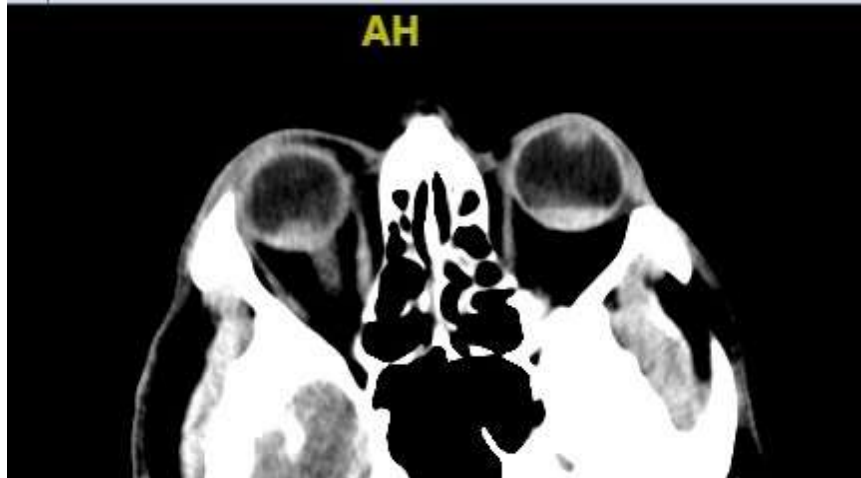


Fig. 1: Axial Non-contrast CT Scan demonstrating bilateral subhyloid and vitreous hemorrhage

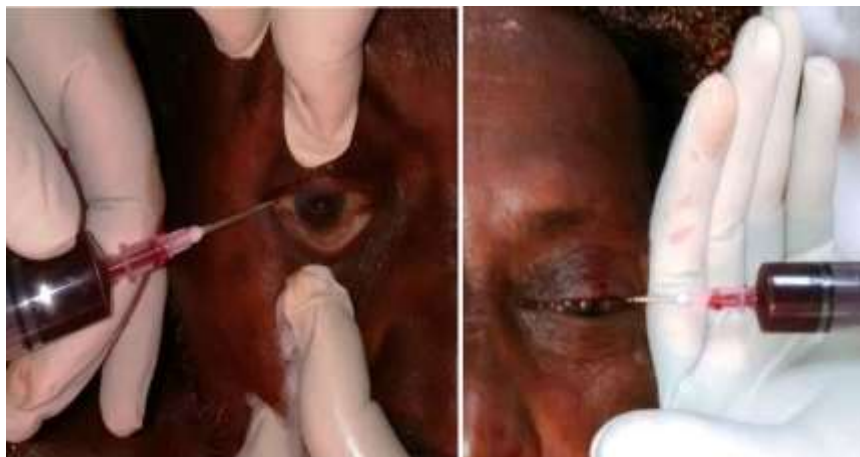


Fig. 2: Demonstration of bilateral vitreous hemorrhage

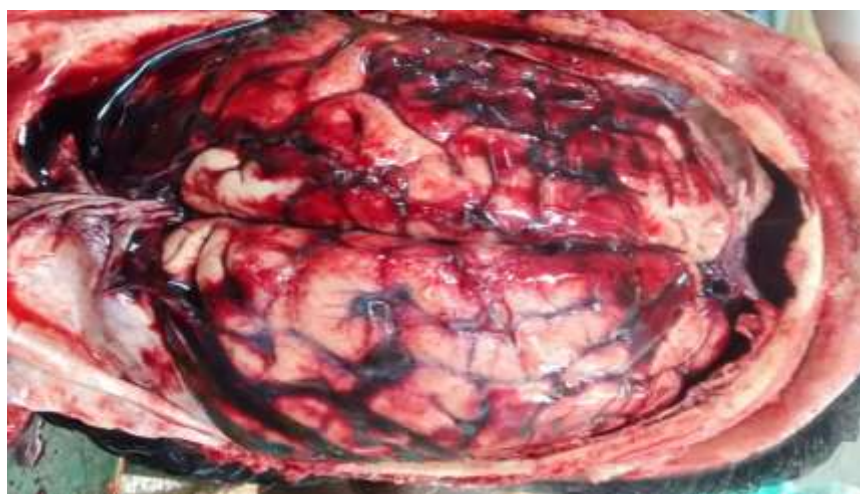

Fig. 3: Diffuse subarachnoid hemorrhage over the cerebrum

Discussion

Terson's syndrome is a retinal or vitreous hemorrhage resulting consequent to subarachnoid hemorrhage.^(5,20-22) It is a relatively common complication of SAH that may require early surgical intervention to prevent hasten recovery and long term loss of vision.^(23,24) Furthermore, it was also suggested that any type of intraocular hemorrhage in patients with SAH may be associated with increased mortality.⁽²⁵⁾ Occurrence of Terson's has been reported with increased mortality in trauma,⁽²⁶⁾ intracranial aneurysm^(5,25) caudal epidural injection^(17,27) cortical venous sinus thrombosis,⁽²⁸⁾ moyamoya disease,^(29,30) intra-arterial angiography, lumbosacral myelomeningocele and iatrogenic bleeding during endoscopic third ventriculostomy.⁽³¹⁾ The complications arising of vitreous hemorrhage mandates the fundoscopic examination and CT scan in cases which are surviving. But in fatal cases of traumatic brain injury subjected to autopsy, it goes generally unnoticed. Retinal nodularity and retinal crescentic hyperdensities were seen in CT in two-thirds of patients with Terson's syndrome. Thus in such cases, CT may be useful in identifying possible Terson's syndrome prior to fundoscopic eye exam.^(23,29) Some studies have suggested that patients with intraocular hemorrhage with SAH have higher mortality rate (50% to 90%) than patients without Terson's syndrome.^(5,12) Terson's syndrome usually occurs in adults, but it has also been reported in infants.⁽³²⁻³⁴⁾ It occurs in 8-19.3% of SAH,⁽³⁵⁻³⁹⁾ 9.1% of intra-cerebral hemorrhages, and 3.1% of traumatic brain injury.⁽³⁹⁾

Vitreous hemorrhage, as an adverse prognostic finding was also determined in patients with SAH in some studies.^(2,25) Neurological complications and mortality rate are worse in patients with Terson's syndrome, than SAH alone.^(5,6,18,39,40,41) In a other study, mortality was 20% when Terson's syndrome was absent and 50% when was present.⁽⁴²⁾ The possibility of Terson's syndrome should be considered in every patient with SAH,⁽⁴³⁾ and it should not be missed during autopsy.

Conclusion

Terson's syndrome is suggestive of increased risk of death without early surgical intervention. Univariate analysis suggests that vitreous hemorrhage is an indicator of poor prognosis in patients with subarachnoid hemorrhage. In such cases of subarachnoid hemorrhage where vitreous hemorrhage is diagnosed by CT scan, immediate surgical management must be considered to reduce mortality. For an accurate assessment of the incidence of Terson's syndrome, and whether vitreous hemorrhage is an independent prognostic variable in patients with subarachnoid hemorrhage, larger, more detailed, and ideally population based prospective studies are required, especially taking into consideration, vitreous hemorrhage assessment in all cases subjected to autopsy with subarachnoid hemorrhage.

References

1. Medele RJ, Stummer W, Mueller AJ, et al. Terson's syndrome in subarachnoid hemorrhage and severe brain injury accompanied by acutely raised intracranial pressure. *J Neurosurg* 1998;88:851-4.
2. McCarron MO, Alberts MJ, McCarron P. A systemic review of Terson's syndrome: Frequency and prognosis after subarachnoid hemorrhage. *J Neurol Neurosurg Psychiatry*. 2004;75:491-3.
3. Ness T, Janknecht P, Berghorn C. Frequency of ocular hemorrhages in patients with subarachnoid hemorrhage. *Graefes Arch Clin Exp Ophthalmol* 2005;243:859-62.
4. Kuhn F, Morris R, Witherspoon CD, Mester V. Terson syndrome: results of vitrectomy and the significance of vitreous hemorrhage in patients with subarachnoid hemorrhage. *Ophthalmology* 1998;105:472-7.
5. Pfausler B, Belcl R, Metzler R, Mohsenipour I, Schmutzhard E. Terson syndrome in spontaneous subarachnoid hemorrhage, a prospective study in 60 consecutive patients. *J Neurosurg* 1996;85: 392-394.
6. Fountas KN, Kapsalaki EZ, Lee GP, et al. Terson hemorrhage in individuals suffering aneurysmal subarachnoid hemorrhage: predisposing factors and prognostic significance. *J Neurosurg* 2008;109:439-44.
7. Rubowitz A, Desai U. Nontraumatic macular holes associated with Terson syndrome. *Retina* 2006;26:230-2.
8. Yokoi M, Kase M, Hyodo T, et al. Epi-retinal membrane formation in Terson syndrome. *Jpn J Ophthalmol* 1997;41:168-73.
9. Sharma T, Gopal L, Biswas J, et al. Results of vitrectomy in Terson syndrome. *Ophthalmic Surg Lasers* 2002;33:195-9.
10. Keithahn MA, Bennett SR, Cameron D, Mieler WF. Retinal folds in Terson syndrome. *Ophthalmology* 1993;100:1187-90.
11. Ritland JS, Syrdalen P, Eide N, et al. Outcome of vitrectomy in patients with Terson syndrome. *Acta Ophthalmol Scand* 2002;80:172-5.
12. Velikay M, Datlinger P, Stolba U, et al. Retinal detachment with severe proliferative vitreoretinopathy in Terson syndrome. *Ophthalmology* 1994;101:35-7.
13. Riddoch G, Goulden C. On the relationship between subarachnoid and intraocular hemorrhage. *Br J Ophthalmol* 1925;9:209-33.
14. Castren JA. Pathogenesis and treatment of Terson syndrome. *Acta Ophthalmol* 1963;41:430-4.
15. Ballantyne AJ. The ocular manifestations of spontaneous subarachnoid hemorrhage. *Br J Ophthalmol* 1943;27:383-414.
16. Ogawa T, Kitaoaka T, Dake Y, et al. Terson syndrome: a case report suggesting the mechanism of vitreous hemorrhage. *Ophthalmology* 2001;108:1654-6.
17. Gibran S, Mirza K, Kinsella F. Unilateral vitreous haemorrhage secondary to caudal epidural injection: A variant of Terson's syndrome. *Br J Ophthalmol*. 2002;86:350-62.
18. Shaw HE, Landers MB. Vitreous hemorrhage after intracranial hemorrhage. *Am J Ophthalmol* 1975;80:207-213.
19. Vanderlinden RG, Chisholm LD. Vitreous hemorrhage and sudden increased intracranial pressure. *J Neurosurg* 1974;41:167-176.
20. Kincaid MC, Yanoff M, Fine BS. Vitreous. In: *Duane's Foundations of Clinical Ophthalmology* 95, vol 3. Lippincott-Raven; 1995:4-5.

21. Schultz PN, Sobol WM, Weingeist TA. Long-term visual outcome in Terson syndrome. *Ophthalmology* 1991;98:1814–1819.
22. Roux FX, Panthier JN, Tanghe YM, et al. Terson syndrome and intraocular complications in meningeal hemorrhages (26 cases) *Neurochirurgie* 1991;37:106–110.
23. Swallow CE, Tsuruda JS, Digre KB, Glaser MJ, Davidson HC, Harnsberger HR. Terson syndrome: CT evaluation in 12 patients. *AJNR Am J Neuroradiol*. 1998;19:743–7.
24. Jusufovic V, Zvornicanin J, Musanovic Z, Sarihodzic S. Terson's syndrome successfully treated with combined therapy. *Med Arh*. 2011;65:375–7.
25. Shaw HEJ, Landers MB, Sydnor CF. The significance of intraocular hemorrhages due to subarachnoid hemorrhage. *Ann Ophthalmol* 1977;9:1403–5.
26. Fang Ko, MD, David L. Knox, MD. The Ocular Pathology of Terson's Syndrome. *Ophthalmology* 2010;117:1423–29.
27. Ling C, Atkinson PL, Munton CG. Bilateral retinal haemorrhages following epidural injection. *Br J Ophthalmol*. 1993;77:316–7.
28. Takkar A, Kesav P, Lal V, Gupta A. Teaching NeuroImages: Terson syndrome in cortical venous sinus thrombosis. *Neurology*. 2013 Aug 6;81(6):e40-1.
29. Kim HS, Lee SW, Sung SK, Seo EK. Terson syndrome caused by intraventricular hemorrhage associated with moyamoya disease. *J Korean Neurosurg Soc*. 2012 Jun;51(6):367-9.
30. Arakawa Y, Goto Y, Ishii A, Ueno Y, Kikuta K, Yoshizumi H, Katsuta H, Kenmochi S, Yamagata S. Terson syndrome caused by ventricular hemorrhage associated with moyamoya disease-- case report. *Neurol Med Chir (Tokyo)*. 2000 Sep;40(9):480-3.
31. Hoving EW, Rahmani M, Los LI, Renardel de Lavalette VW. Bilateral retinal hemorrhage after endoscopic third ventriculostomy: iatrogenic Terson syndrome. *J Neurosurg*. 2009 May;110(5):858-60.
32. Bhardwaj G., Jacobs M.B., Moran K.T., and Tan K.: Terson syndrome with ipsilateral severe hemorrhagic retinopathy in a 7-month-old child. *J AAPOS* 2010; 14: pp. 441-443.
33. Kapoor S. Terson syndrome: an often overlooked complication of subarachnoid hemorrhage. *World Neurosurg*. 2014 Jan;81(1):e4.
34. Billotte C, Lecoq PJ, Sostenes C et al. Terson's syndrome and a case of post-traumatic syndrome in an infant. *Bull Soc Ophthalmol Fr*. 1988;88:111–114.
35. Iuliano L, Fogliato G, Codenotti M. Intrasurgical imaging of subinternal limiting membrane blood diffusion in terson syndrome. *Case Rep Ophthalmol Med*. 2014;2014:689793.
36. Michalewska Z, Michalewski J, Nawrocki J. Possible methods of blood entrance in Terson syndrome. *Ophthalmic Surg Lasers Imaging*. 2010 Nov-Dec;41 Suppl:S42-9.
37. Morris R., Kuhn F., and Witherspoon C.D.: Hemorrhagic macular cysts. *Ophthalmology* 1994;101:1.
38. Morris R., Kuhn F., Witherspoon C.D., et al: Hemorrhagic macular cysts in Terson's syndrome and its implications for macular surgery. *Dev Ophthalmol* 1997; 29: pp. 44-54.
39. Czorlich P, Skevas C, Knospe V, et al. Terson syndrome in subarachnoid hemorrhage, intracerebral hemorrhage, and traumatic brain injury. *Neurosurg Rev*. Epub 2014 Aug 31.
40. Fountas KN, Kapsalaki EZ, Lee GP, et al. Terson hemorrhage in patients suffering aneurysmal subarachnoid hemorrhage: predisposing factors and prognostic significance. *J Neurosurg*. 2008 Sep;109(3):439-44.
41. Manschot WA. Subarachnoid hemorrhage. Intraocular symptoms and their pathogenesis. *Am J Ophthalmol*. 1954;38:501-505.
42. Gutierrez Diaz A, Jimenez Carmena J, Ruano Martin F, Diaz Lopez P, Muñoz Casado MJ. Intraocular hemorrhage in sudden increased intracranial pressure (Terson syndrome). *Ophthalmologica*. 1979;179(3):173-6.
43. Bavikatte G, Eshiett M, Hassoon A. Terson's syndrome: Experience of two patients in acute Neurorehabilitation ward. *IJPMR*. 2011;22:102–4.