

## Analysis of postmortem findings of asphyxial deaths due to Hanging in urban region of Karnataka

V. Dekal<sup>1</sup>, Shruthi P<sup>2\*</sup>

<sup>1</sup>Associate Professor, <sup>2</sup>Assistant Professor, Dept. of Forensic Medicine & Toxicology, Saveetha Medical College & Hospital, Chennai

**\*Corresponding Author:**

Email: drshruths@gmail.com

### Abstract

Hanging, a form of deliberate self-harm accounts for a large proportion of autopsies which forensic experts come across in their clinical tenure at various hospitals in almost all parts of India. A retrospective study was conducted in the Department of Forensic Medicine and Toxicology, Kempegowda Institute of Medical Sciences, Bangalore from April 2004 to March 2006, with an objective to study the post mortem findings in autopsy cases of hanging. Out of 810 autopsies, 27.9% cases were that of hanging. Most cases were atypical (95.6%) and complete hanging (90.3%) with the ligature mark situated above the thyroid cartilage. 34.1% of cases had dried salivary stain at the angle of mouth and 1.3% cases showed involuntary discharge. The incidence of fracture of hyoid bone was 15.49% of cases. This study depicts the possible findings in a suspected case of hanging which ought to be anticipated to avoid any flawed opinion.

**Key Words:** Violent asphyxia, Hanging, Autopsy, Salivary stains, Hyoid bone, Thyroid cartilage.

Access this article online	
Quick Response Code:	Website: www.innovativepublication.com
	DOI: 10.5958/2394-6776.2016.00027.8

### Introduction

Hanging, a form of violent asphyxia, is due to constriction of neck as a result of suspension in such a manner that the weight of the body or a part of the victim's body pulls upon the ligature.

In certain cases of deaths resulting from hanging, the ligature mark may create uncertainty.

All the characteristic features maybe present infrequently due to the variable amount of pressure applied on the neck. Hence it mandates a proper assessment of various post-mortem findings under such circumstances.

In this study an attempt has been undertaken in the view to gain, further knowledge and insight into the gross post mortem features of asphyxial deaths due to hanging in Bangalore South region.

### Materials and Methods

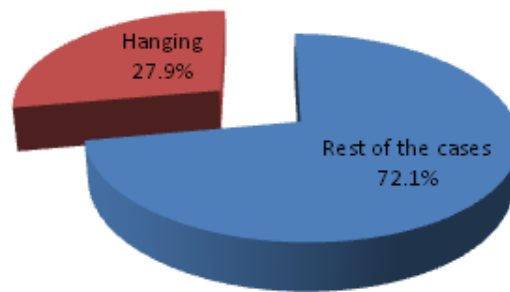
The study consisted of 810 medico-legal autopsy performed in the Department of Forensic Medicine, Kempegowda Institute of Medical Sciences, Bangalore, Karnataka during the period of 2 years (from April 2004 to March 2006). Out of total 810 medico-legal autopsies, 226 were hanging victims (27.9%).

Necessary information for the study was gathered from Police, inquest report and hospital treatment records. The relatives, friends, and neighbors of the victims were also taken separately for data collection. In few cases additional information was gathered by a visit to the scene of crime or by reviewing the photographs.

A detailed proforma for recording the details of hanging was prepared for filling the observation of the present study. The information thus collected, was statistical analyzed.

### Results and Discussion

#### Profile of Hanging Cases



**Fig 1: Profile of hanging cases**

During this study period, 810 cases were brought for post-mortem examination out of which 226 (27.9%) deaths were due to hanging. (Fig. 1)

**Table 1: Typical and Atypical hanging**

Typical/ Atypical	Position of knot			Total
	Back	Left	Right	
Typical	10 (100.0%)	-	-	10(4.4%)
Atypical	-	93(43.1)	123(56.9%)	216(95.6%)
	10(4.4)	93(41.2)	123(54.4)	226

Out of 226 cases, typical hanging was found only in 10 cases (4.4%) whereas most of the cases 216 (95.6%) were atypical hanging, with the position of knot on left or right side. Knot was on the right side of neck in 123 cases (56.9%) (Table 1). Similar findings were observed in the studies conducted by other authors.<sup>[1,2]</sup>

**Table 2: Type of Hanging (Complete/ Partial)**

Type of Hanging	Number	Percentage
Complete	204	90.3
Partial	22	9.7
Total	226	100.0

In the present study complete hanging was seen in 90.3% deaths. Partial hanging was taking lives mostly, accounted for 22(9.7%) deaths (Table 2). This is in accordance with studies by few authors<sup>[3,4]</sup> but not in agreement with others.<sup>[1,2]</sup>

**Table 3: According to the Level of the Ligature Mark**

Level of ligature mark	Cases	Percentage
Above the thyroid cartilage	192	84.95
Overriding the thyroid cartilage	19	8.41
Below the thyroid cartilage	15	6.64
Total	226	100

In our study, it was observed that in 192 cases, the level of ligature mark was above the thyroid cartilage, below the thyroid cartilage in 15 cases and overriding the thyroid cartilage in 19 cases (Table 3). This was also observed in various other authors' studies.<sup>[1,4]</sup>

**Table 4: Salivary Stains**

Salivary Stain	Number	%
Present	77	34.1%
a) Left (n=77)	40	51.9%
b) Right (n=77)	37	48.1%
Absent	149	65.9%
Total	226	100.0%

Dribbling of saliva, surest sign of antemortem hanging, was found in 77 cases (34.1%) of hanging. The findings are consistent with those of Ashok Kumar Samanta et al<sup>[5]</sup> who observed 32.31% cases with dribbling of saliva.(Table 4)

In 175 (77.43%) cases, postmortem staining was present over the back, indicating the body was noticed by the relatives within 2 hours of suspension, removed and placed in a prone position. Involuntary discharge of feces was present in 1 cases and semen on glans penis present in 2 cases of hanging. In 226 cases of hanging, hyoid bone was fractured in 35 cases (15.49 %). This is in agreement with a study by various authors from Gujrat.<sup>[6,7]</sup>

**Table 5: Hyoid Bone Fracture**

Age in Years	Hyoid Bone Fracture					
	Present (n=35)		Absent (n=191)		Total (n=226)	
11-20	1	2.9	41	21.5	42	18.6
21-30	1	2.9	100	52.4	101	44.7
31-40	6	17.1	40	20.9	46	20.4
41-50	14	40.0	9	4.7	23	10.2
51-60	8	22.9	1	0.5	9	3.9
>60	5	14.3	-	-	5	2.2
Inference	The incidence of fracture of hyoid bone in hanging is significantly more (61 times) in age group above 40 years in comparison to the age group below 40 years ( $X^2 = 111.17$ , $p < 0.001$ ).					

27 cases out of the 35 were above the age group of 40 years. The incidence of fracture of hyoid bone is significantly more in the age group above 40 years when compared to that below 40 years (Table 5). It has been demonstrated in numerous studies that the incidence of fractures increases with age<sup>[2,8]</sup> because neck structures become calcified and more brittle in middle and later life<sup>[9,10]</sup>.

### Conclusion

Age is doubtlessly one of the most important variable contribute to the fracture of the neck structure in hanging. The fracture of hyoid bone should preferably be confirmed by radiography and histology before cataloging it as an ante-mortem fracture. Dribbling of saliva present in case of hanging is a sure sign of antemortem hanging. Other post mortem findings like involuntary discharge of urine, fecal matter, semen on glans penis, postmortem staining etc. will help in the diagnosis when ligature marks are not clear.

**Conflicts of Interest:** None

**Funding:** None

**Ethical Approval:** Obtained

### References

1. Sharma BR, Harish D, Sharma S, Singh H. Injuries to structures in deaths due to constriction of neck, with special reference to hanging. *J Forensic Leg Med.* 2008 July;15(5):298-305.
2. Sharma BR, Singh VP, Harish D. Neck structure injuries in Hanging-comparing retrospective and prospective studies. *Med Sci. Law.* 2005;45(4):321-330.
3. M Ahmad, MZ Hossain. Hanging as a Method of Suicide: Retrospective Analysis of Postmortem Cases. *JAFMC Bangladesh.* 2010;6(2):37-39.
4. T. Saisudheer, T. V. Nagaraja. A study of ligature mark in cases of hanging deaths. *Int. J Pharm Biomed Sci.* 2012;3(3):80-84.
5. Ashok Kumar Samanta, Soumya Rajan Nayak. Newer trends in hanging death. *Journal of Indian Academy of Forensic Medicine.* 2012;34(1):37-39.
6. M.M.M Shaikh, H. J. Chotaliya, A.D. Modi, A. P. Parmar, S. D. Kalele. A study of gross postmortem findings in cases of Hanging and Ligature Strangulation. *Journal of Indian Academy of Forensic Medicine.* 2013 Jan-March;35(1):63-65.
7. Sarangi M. P. "Ligature marks" – In Forensic pathologist's perspective. *Journal of Forensic Medicine and Toxicology.* 1998Jan – June;15(1):99-102.
8. S. Nikolic, J. Micic, T. Atanasijevic, V. Djokic, D. Djonic. Analysis of neck injuries in hanging. *Am. J. Forensic Med. Pathol.* 2003;24(1):179-182.
9. B. Knight, P. Saukko, *Fatal Pressure on the Neck in: Knight's Forensic Pathology*, 3th ed., Arnold Publishers, London, England, 2004:368-394.
10. H.M. Garvin. Ossification of laryngeal structures as indicators of age. *J. Forensic Sci.* 2008;53(1):1023-1027.