

## Incidence of Carotid tears in cases of deaths due to hanging – a prospective study conducted in Govt. Stanley Medical College, Chennai

S. Balusubramanain<sup>1,\*</sup>, A. Gokulakrishnan<sup>2</sup>

<sup>1</sup>Associate Professor, <sup>2</sup>Assistant Professor, Department of Forensic Medicine and Toxicology, Govt. Stanley Medical College and Hospital, Chennai, India

**\*Corresponding Author:**

Email: drgokulfm@gmail.com

### Abstract

The present study was carried out between 2012 and 2015. A total of 5068 autopsies were conducted of which 15.7% (n – 764) cases were deaths due to hanging. The commonest ligature materials of choice were Sari. In 68% of the cases, hanging was complete. Females (n – 343) and males (n – 421) were equally affected. The major age group involved in both the sexes was of 31–40 years, contributing to 60.7% of the self-suspension. Majority of the ligatures had a fixed type of knot contributing to 97.73% (n – 658) of the suspensions and only 2.27% (n – 106) showed slip knot. Based on position of knot all cases were divided into four categories according to the position of the knot on the neck (I–IV) and further based on position of the body they are further classified into complete and partial hanging (A & B) Of the 764 cases of hanging, transverse laceration in the intimal layer was seen in 412 cases in which most of them were identified by histological examination rather than naked eye examination, Amongst complete hanging (IA, IIIA, IVA) shows more incidence of carotid tear than posterior partial hanging (II B).

**Key words:** Hanging, Suicide, Ligature knot, Carotid tear, Intimal tear.

Access this article online	
Quick Response Code:	Website: www.innovativepublication.com
	DOI: 10.5958/2394-6776.2016.00020.5

### Introduction

Hanging is one of the commonest modes of deaths among suicidal cases and death due to hanging is not unusual across the world, this makes the majority of Asphyxia deaths<sup>1</sup>. Deaths by ligation of Neck are in practice from the immemorial time and before advent of civilization.

The present study on Incidence of carotid tear in cases of hanging makes a detailed autopsy examination and tries to compare and correlate established findings by previous authors and an attempt is made to establish newer trends and deviations from the earlier studies. And a newer dimension like position of knot and Histopathological examination of carotid artery corresponds to the ligature mark has been added to this present study and highlights microscopic events.

Ligature marks themselves are mainly a postmortem phenomenon. The most important signs in the diagnostics of hanging are internal neck injuries. Such vital findings are evidence of a pre-mortem origin of hanging and Injury to cervical vessels as a result of hanging is one such basic diagnostic sign. The best known is the so-called Amussat's sign (Fig. 1a, 1b & 2) i.e., transverse laceration in the intimal layer of the

carotid artery.<sup>(2)</sup> It is possible to have multiple tears and sub intimal hematomas can be found around them (Fig. 3). It must be emphasized that carotid tears are not specific for hanging only, but can also be caused by blunt neck trauma, extreme overstretching of neck or whiplash-injuries too.<sup>(3)</sup>

The objective of this paper is evaluating the incidence of carotid tear in cases of hanging by both gross and histopathological examination and to establishing newer trends like incidence of carotid tear based on position of knots.

### Materials and Methods

A prospective study on incidence of carotid tears in cases of hanging was conducted in the Department of Forensic Medicine & Toxicology, Stanley medical college between 2012 and 2015, A total of 5068 Autopsies were conducted of which Suicidal Hanging contributed to 15.7% (n – 764) of cases among 4 cases of hanging were excluded because of advanced putrefaction, For the identification and quantification of intimal tears in the carotid arteries in correspondence to the location of ligature knots which was determined on the basis of the appearance of the ligature mark, its course, depth and width, including photo documentation of the place where the body was found.

Based on position of knot all cases were divided into four categories according to the position of the knot on the neck I–IV (Fig. 4). In cases of anterior hanging (I), the ligature knot was situated in the anterior midline, the limit was the inner side of the sternocleidomastoid muscle. In cases of posterior hanging (II), the ligature knot was situated in the

posterior midline, the limit was the posterior aspect of the mastoid process. When the ligature knot was placed on the sides of the neck or head between mentioned limits (on the right, or on the left), then the category was right hanging (III) or left hanging, respectively (IV).

Furthermore, individual cases were divided according to the completeness of the victim's suspension into two main subcategories: free body suspension (A, complete hanging) and incomplete body suspension (B, incomplete hanging). Internal findings were noted by bloodless dissection of neck, and neck structures were dissected layer by layer. The carotid artery was evaluated after evacuation of the neck organs; the intimal layer of these vessels was visualized by longitudinal cutting with the blunt arm of scissors. Carotid artery tear was identified by both gross and histological examination (Fig. 2A & 2B).

Incidence of carotid tear was studied based on above classification and both right and left carotid artery corresponding to ligature mark were subjected for histopathological examination to avoid false positives like artefacts due to dissection and to avoid missing of hair line tears in carotid arteries.

### Observations

- a. In the group of 764 cases of hanging, there were (n – 421) males and (n – 343) Females, The major age group affected in both the sexes was in the range of 31–40, contributing to 60.76% (n – 436) of the self- suspension. The least affected ages were in children less than 10 years (n – 01).
- b. The commonest ligature materials of choice were Sari (n – 468; 35.76%). The least common ligature material of choice was Waist Belt (n – 2; 0.76%). The other materials used were Plastic Rope (n – 228; 10.68%), Bed Sheet (n – 124; 8.33%) and Cotton Rope (n – 97; 7.20%) in decreased order of appearance. Majority of the

- ligatures had a fixed type of knot contributing to 97.73% (n – 658) of the suspensions and only 2.27% (n – 106) showed slip knot.
- c. Of the total 764 cases of self-suspension, 521(68%) of the hanging were complete and 239(32%) were due to Partial Hanging.
  - d. In cases of complete hanging (A) carotid tear was seen in 324 cases of 521 (77.9%) in that 86 cases tear was identified by gross examination, remaining 238 cases were identified by histological examination, similarly in partial hanging (B) with incomplete body suspension carotid tear was identified in 88 cases of 239 (13.7%) of which 16 cases were identified by gross examination. (Table 1 & 2).
  - e. Of the 764 cases of hanging, transverse laceration in the intimal layer was seen in 412 cases in which 102 cases were seen by naked examination.(Chart -1)
  - f. Amongst 188 cases of Anterior hanging carotid tear was seen in 139 cases in which 106(IA) cases in complete hanging and 33(IB) cases in partial hanging and in most of the cases bilateral tear was identified by both gross and histopathological examination.
  - g. In 192 cases of right lateral hanging 122 cases had carotid tears in that 98(IIIA) cases were complete hanging and 24(IIIB) cases were partial hanging, in most cases tear restricts to right carotid only.
  - h. In 182 cases of left lateral hanging 147 cases had carotid tears in which 116(IVA) cases were complete hanging and 31(IVB) cases were partial hanging, and in most cases tear restricts to left side only.
  - i. Of 202 posterior hanging only in 4 cases carotid tear was identified in which most of them were seen in complete hanging and in one case carotid tear seen in partial hanging.(Table 3)

**Table 1: Shows No of cases showed carotid tear in complete and partial hanging**

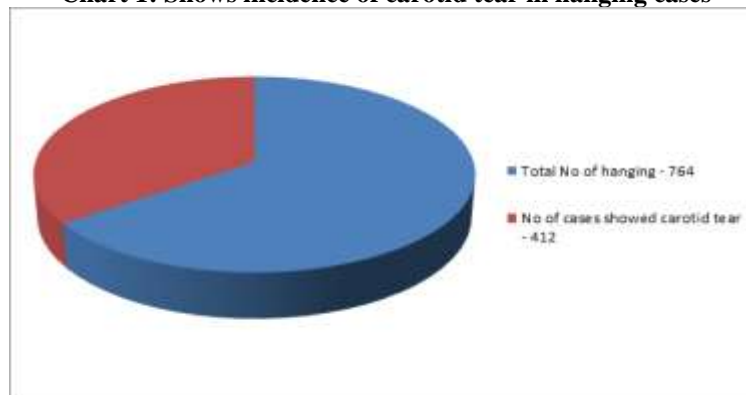
Type of Hanging	No of cases studied	Total No of cases showed carotid tear
Complete Hanging (A)	521	324
Partial Hanging (B)	239	88

**Table 2: Shows No of cases showed carotid tear by naked eye examination and histological examination in complete and partial hanging**

Type of Hanging	No of cases shown carotid tear by naked eye examination	No of cases shown carotid tear by histopathological examination (including gross)
Complete hanging (a)	86	238
Partial hanging (b)	16	72

**Table 3: Shows No of cases showed carotid tear based on position of knot**

Position of Knot	No of cases showed carotid tear in complete hanging(A)	No of cases showed carotid tear in partial hanging (B)
Anterior hanging (i)	106	33
Posterior hanging (ii)	03	01
Right lateral hanging (iii)	98	24
Left lateral hanging (iv)	116	31

**Chart 1: Shows incidence of carotid tear in hanging cases**

## Discussion

The present prospective study was conducted between 2012 to 2015. A total of 5068 cases were examined of which deaths due to hanging comprised about 764 cases. In that females and males were equally affected contributing to 421 and 348 cases respectively and most of the cases within the age group of 31 – 40 years due to influence of cultural and socioeconomic factors.

In the present study the commonest choice of ligature material used was sari due to its easy viability in the houses. The present study also indicated the fact that 88% of the hangings were complete. In the present study the most preferred knot was the fixed knot, contributing to 97.73% (n – 258) of cases.

The present study showed 412 carotid tear amongst 764 hanging cases. In that 78.6% cases showed carotid tear and most of them were identified by histological examination rather than by naked eye examination. Results show incidence of carotid tear more common in complete hanging.

The absence of transverse tears in the intimal layer of carotid arteries in a group of individuals where the ligature knot was situated at the posterior midline was a surprising observation. It is possible that in such cases the ligature does not produce intense pressure upon the area of the neuro-vascular bundles of the neck.<sup>(4)</sup> This observation, however, was not found in the latest studies. Lacerations or gross changes in the intimal layer of the carotid arteries were seen more in cases of lateral hanging (III, IV) on the same side of the suspension point, i.e., at the point of the compression acting upon the neck organs. Factors like convulsive phase during the process of asphyxia on the ligature also contribute to this process.

It is possible to consider that the occurrence of intimal tears in the carotid artery area relates not only to the traction but also to the direct pressure due to compression by the knot on the neck structures. The acting pressure of the ligature very likely leads to deformation and fixation of the part of the artery below the ligature to the deeper tissue structures of the neck. The proximal section of the artery below the point of its fixation is then exposed to traction forces that lead to a forced, downward stretching of this part of the artery.<sup>(5)</sup> A combination of forced compression of the artery and its longitudinal stretching could be the most frequent mechanism leading to the occurrence of ruptures in the intimal layer of carotid arteries in hanging. This suggestion is supported by the bilateral occurrence of intimal tears in the carotid arteries in cases of anterior hanging, where a combination of the extreme radial pressure of the tightening rope and high-powered axial traction is always present.<sup>(6)</sup> However it states that subjecting carotid arteries corresponding to ligature mark yields more number of positive results.

Most of the Autopsy studies published so far showed a state of relatively low frequency of occurrence of intimal ruptures in the walls of carotid arteries. In a study conducted by Schroeder and Saturnus 7.4% of 204 cases of hanging showed carotid tear.<sup>(7)</sup> Surez-PeÇaranda et al. in 9.1% of 228 cases of hanging<sup>8</sup>, Lesser in 14% of 50 cases of hanging, Laiho in 16% of 124 cases of hanging.<sup>(9)</sup>

However in our study a statistically significant association was noted and it has been supported by similar studies conducted by Petr Hejna on Amussat's Sign in Hanging-A Prospective Autopsy Study.<sup>(10)</sup>

The present study conducted on 764 cases of which 412 cases showed carotid tear. Interesting fact observed

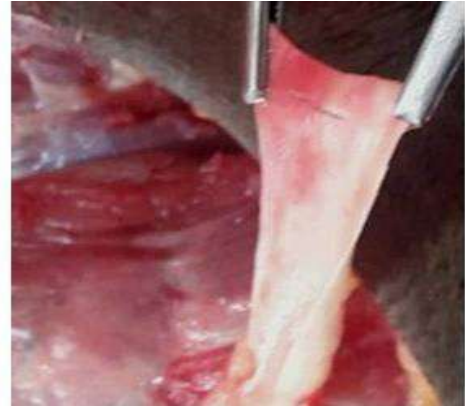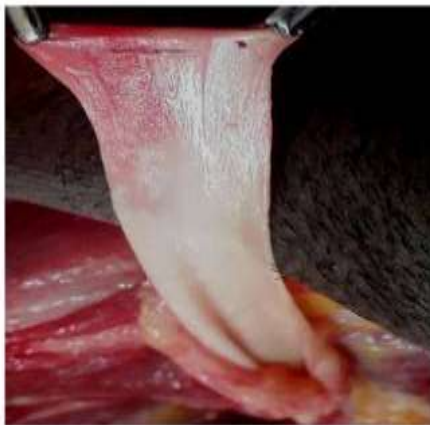was naked eye appearance of carotid tear were less but histological examination showed more number of tears.

### Conclusion and Recommendations

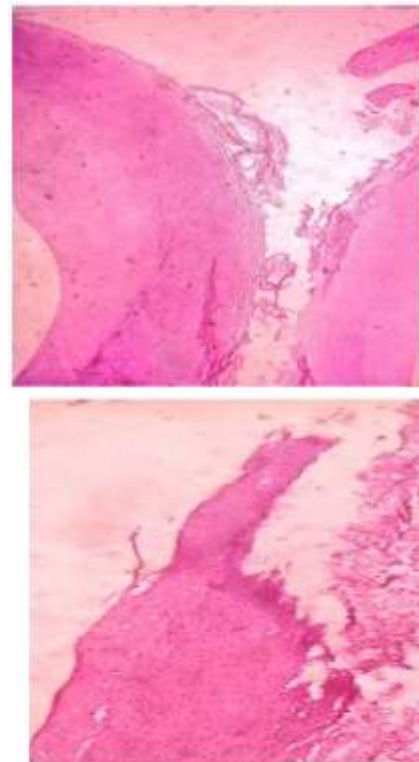
In the present study females and males were equally affected contributing to 421 and 348 cases respectively amongst 78.6% cases showed carotid tear and most of them were identified by histological examination rather than by naked eye examination, and results show incidence of carotid tear more common in complete hanging.

A statistically significant association between the position of the ligature knot on the neck, completeness of the body's suspension, and the occurrence of ruptures in the intimal layer of carotid arteries was found and most of the cases were identified by histological examination, it is necessary to send every case of hanging to histological examination to avoid missing that finding. Amongst complete hanging (IA, IIIA, IVA) shows more incidence of carotid tear than posterior partial hanging (II B).

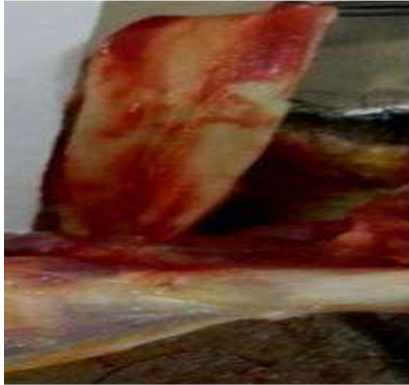The study results also shows that intimal tears to carotid arteries as a result of hanging could be produced by direct pressure of the ligature on the neck organs as well as by compression of knot over the vascular bundle and indirectly by stretching neck structures because of the gravitational drag produced by the victim's body weight and Factors like convulsive phase during the process of asphyxia on the ligature also contribute to this process. However it states that subjecting carotid arteries corresponding to ligature mark yields more number of positive results and these finding help to differentiate hanging cases from strangulation and post mortem hanging.



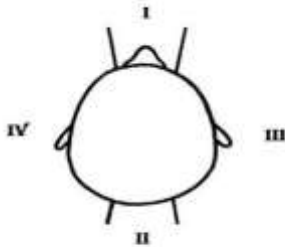
**Fig. 1(A & B): Shows sub intimal hematoma with carotid artery tear corresponds to the ligature mark**



**Fig: 2 A shows histological image of micro carotid tear seen only by histological examination and 2B shows gross carotid tear seen by both gross and histological examination**



**Fig. 3.** Shows multiple sub intimal hematoma with carotid artery tear corresponds to the ligature mark



**Fig. 4:** Shows based on position of knot all cases were divided into four categories (I–IV)

### References

1. Brinkmann B. Erh\_ngen. In: Brinkmann B, Madea B, editors. Handbuch gerichtliche Medizin. Band I. Heidelberg, Germany: Springer Verlag, 2004;761–76.
2. Amussat JZ. Recherches experimentales sur les blessures des art\_eres et des veines. R sumes des trois m\_mmoires lus \_ l'Academie royal de science. Paris, France: Dupont, 1843.
3. Maxeiner H, Finck GA. Traumatic cerebral infarct in multistage dissection of the extracranial internal carotid artery. Unfallchirurg 1989;92:321–7.
4. Su\_rez-PeÇaranda JM, Alvarez T, Migu\_ns X, Rodr\_guez-Calvo MS, de Abajo BL, Cortes\_4o M, et al. Characterization of lesions in hanging deaths. J Forensic Sci 2008;53:720–3.
5. Tracqui A, Fonmartin K, G\_raub A, Pennera D, Doray S, Ludes B. Suicidal hanging resulting in complete decapitation: a case report. Int J Legal Med 1998;112:55–7.
6. Rothschild MA, Schneider V. Decapitation as a result of suicidal hanging. Forensic Sci Int 1999;106:55–62.
7. Schr\_oder R, Saternus KS. Stauungszeichen im Kopfbereich und Ver\_nderungen am Gehirn beim suicidalen Erh\_ngstod. Z Rechtsmed 1983;89:247–65.
8. Su\_rez-PeÇaranda JM, Alvarez T, Migu\_ns X, Rodr\_guez-Calvo MS, de Abajo BL, Cortes\_4o M, et al. Characterization of lesions in hanging deaths. J Forensic Sci 2008;53:720–3.
9. Lesser A. ber die lokalen Befunde beim Selbstmord durch Erhngen. Vierteljahresschr Gerichtl Med 1881;35:201–8.

10. Petr Hejna, Amussat's Sign in Hanging - A Prospective Autopsy Study. J Forensic Sci, January 2011, Vol. 56, No. 1