

Content available at: <https://www.ipinnovative.com/open-access-journals>

Indian Journal of Forensic and Community Medicine

Journal homepage: <https://www.ijfcm.org/>

Case Report

A rare cases of ferrous sulphate poisoning- A case study

Manishi Shriwas^{1,*}, Dinesh Sharma², Vaishali Sinha³

¹Centurion University of Technology & Management, Vizianagaram, Andhra Pradesh, India

²CAPT (BPR&D), Bhopal, Madhya Pradesh, India

³Kalinga University, Raipur, Chhattisgarh, India



ARTICLE INFO

Article history:

Received 16-08-2023

Accepted 11-09-2023

Available online 27-10-2023

Keywords:

Ferrous sulphate

Green vitrol

ABSTRACT

A poison is a substance which when administrated, inhaled or ingested is capable of causing deleterious effect on the human body. The circumstances may be suicidal, homicidal or accidental. A suicidal poison of choice must be cheap, easily available and capable of being administered is any food or drink. It must have pleasant taste and no repulsive smell. The action of poison may be local, remote, combined and general. The preparations of iron salt, which are largely used in medicine are mostly prepared from sulphate, carbonate and perchloride of iron. When these salt are administered in large doses, they produce poisonous symptoms and may even cause hemosiderosis as a manifestation of chronic poisoning. Iron sulphate (ferrous Sulphate, FeSo₄) is commercially known as green vitriol of sulphate. It forms green, efflorescence monosymmetric crystals on exposure to the atmosphere. It is freely soluble in water. It is used in making blue ink and dyes, but sometimes as a pesticide. In this case study, we'll talk about a woman who died after consuming an corrosive drug at home. For medico-legal purposes, it was critical to correlate autopsy results with medical care records and the place of the incident.

This is an Open Access (OA) journal, and articles are distributed under the terms of the [Creative Commons Attribution-NonCommercial-ShareAlike 4.0 License](https://creativecommons.org/licenses/by-nc-sa/4.0/), which allows others to remix, tweak, and build upon the work non-commercially, as long as appropriate credit is given and the new creations are licensed under the identical terms.

For reprints contact: reprint@ipinnovative.com

1. Introduction

Poison is any substance which is given more than their effective dose as a result capable of causing the illness or death of a living organism.¹ Poison is classified as corrosive, irritant, systematic and miscellaneous. Under Indian penal code any poisonous substance is described under sec 284. Under the poisons one of this is ferrous sulphate.² Basically it is the component of iron which is member of group 8 in second series of periodic table with atomic number 26. Its valency is totally 8 but in rare condition it shares all its valency. The component of iron is found by sharing +2, and +3 valency and form ferrous sulphate and ferric sulphate respectively. Ferrous sulphate is irritant in nature and come under inorganic poison within the class of transition metal

oxoanionic compound causing local action on body. Ferrous sulphate which is pale green in color commonly called green vitrol or copperas or kasisa^{3,4} & herakashi. Formulate as Feso₄.7H₂o thus also called Heptahydrate. If iron is added to sulphuric acid, it results as ferrous sulphate. With sharing +3 valency by the oxidation of ferrous sulphate with nitric acid or hydrogen peroxide, it forms ferric sulphate which is yellow in color. Ferrous sulphate is frequently used as a drug for treatment of anemia as well as useful in enzymatic action, DNA replication and repair in body. Ferrous sulphate acute oral LD- 50 at 132-881mg⁵ & chronic oral-56-65mg. As after taking of any drug more than the particular amount it works as the poison, over of ferrous sulphate is known as ferrous sulphate poisoning. The mode of administration of poison in the body is through skin/ eye in contact with dust and mints, ingestion by swallowed or inhalation cause local effect on respiratory system. When the corrosive gets

* Corresponding author.

E-mail address: minishriwas2015@gmail.com (M. Shriwas).

into contact with body tissue like the mouth, eyes, skin, gastrointestinal tract, or respiratory system, they greatly damage those areas resulting in necrosis that is liquefactive and penetrates. The grades corrosive injuries depend on when they occur, kind, quantity, or concentration of the corrosive consumed.⁶ This leads to different impacts in the body with the passing of time which can be classified into 4 stages. In the early stage vomit and dark grey bloody stool, 2nd stage sets after 6-12 hours, 3rd stage with renal failure, shock, metabolic acidosis, hypoglycaemia occur and the last stage in which intestinal obstruction, pyloric stenosis, gastric scarring, necrotizing effect on stomach & intestine occurs. As in toxic condition it is harmful for the liver,⁷ bone marrow, spleen, muscle also. This paper consist of the real time case occurred with the findings in the crime scene & report given by the forensic lab after examination of the findings.

2. Case Study

Crime scene marked as R where the body of a female in unconscious state was found in marked place B. The eyes of the corpse was closed without any force in the eyelids, the mouth was in half open condition, hands were straight and parallel to each other, fingers were closed, legs were straight and parallel in position without any angle making with respect to the surface. During investigation, the body of the Corpse had saree, blouse, and peticoat in the organized manner, no sign of struggle was observed by looking at the clothes arrangement. In talking about the crime scene which is marked C, a white color rolling board was found with some greenish material over it. Evidence marked E was empty liquor bottle at the site of gas cylinder. Evidence marked F was 600ml empty bottle of pepsi brand. (The marking is given according to the RFSL sketching during the sketching of crime scene).

2.1. Findings

1. White color material in dry condition was seen around the open mouth.
2. Some vomit material in white color on the clothes of corpse was seen.
3. Cold drink bottle of pepsi with some miscellaneous material of 50ml was left.
4. As female is right-handed, the pepsi bottle was found on right hand side of the corpse.
5. White color rolling board containing greenish color traces over it was found.
6. Roller also had minute traces of green color around it.

2.2. Post-mortem appearances

When the corpse underwent the internal examination through post mortem the mucosa membrane of stomach & intestine was red in color due to the corrosive nature of

ferrous sulphate. Inflammation with haemorrhages through out the oesophagus was observed. When the stomach and intestine was opened it was found in necrosis condition. Hepatic necrosis & degeneration of tubules of kidney was also observed. The pigment of iron was present in the tissues after intake of the poison.

The following shows the action by the Figure 1.

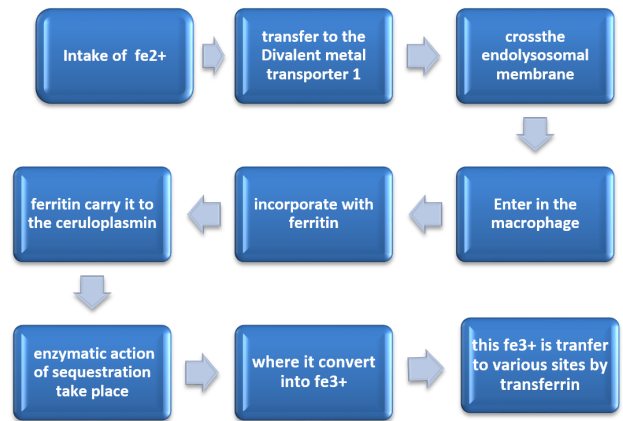


Fig. 1: Mechanism of action

3. Result

As per the RFSL report, result for the test of Ferrous and sulphate was found positive in the viscera of corpse which follows the standard parameters of the text given by the authority. The medical report said that the death occurred due to asphyxia with some traces of ferrous sulphate found in tissues.

4. Conclusion

Iron is most important material in human body but in limited concentration, over which it can cause damage to body as in following mechanism.⁸ The absorption over tissue increases upto 30% in deficiency condition and 60% of volume distribution over erythrocytes and then in myoglobin. Homicidal cases are rare for one reason and that is due to the color of ferrous sulphate which is easily seen. Suicidal cases are rarely seen but this case study confirms the death of the person due to the intake of the ferrous sulphate. Accident cases of the children death is seen mostly due to easily availability in house and its tablet coated with the sugar which attract the child.⁹ It becomes fatal for the woman who are pregnant and taking more amount of iron tablets also.¹⁰

5. Source of Funding

None.

6. Conflict of Interest

None.


References

1. Bisset NG. One man's poison, another man's medicine? *J Ethnopharmacol.* 1991;32(1-3):71–81.
2. Thomson J. Ferrous sulphate poisoning. *Br Med J.* 1947;(1):645. doi:10.1136/bmj.1.4505.640.
3. Sharma R, Prajapati PK. Pharmaceutico-therapeutic vistas of kasisa (green vitriol) in Ayurveda. *Int J Ayurveda Pharm Res.* 2016;2(1):36–47.
4. Karpenko V, Norris JA. Vitriol in the History of Chemistry. *Chemicke Listy.* 2002;96(12):997–1005.
5. Baranwal AK, Singhi SC. Acute iron poisoning: management guidelines. *Indian Pediatr.* 2003;40(6):534–40.
6. Shandil A, Abhay A, Ranjan K, Kumar D, Ali I, Kumar S. An autopsy based study of corrosive acid poisoning and its medico-legal aspects - A case report. *Indian J Forensic Community Med.* 2023;10(2):96–8.
7. Robertson A, Tenenbein M. Hepatotoxicity in acute iron poisoning. *Hum Exp Toxicol.* 2005;24(11):559–62.
8. Ferrous Sulfate Environmental and Toxicological Information. Available from: [https://www.affinitychemical.com/ferrous-sulfate-](https://www.affinitychemical.com/ferrous-sulfate-environmental-and-toxicological-information/)

[environmental-and-toxicological-information/](https://www.affinitychemical.com/ferrous-sulfate-environmental-and-toxicological-information/).

9. Ferrous sulfate. Available from: <https://go.drugbank.com/drugs/DB13257>.
10. Abhilash KPP, Arul JJ, Bala D. Fatal overdose of iron tablets in adults. *Indian J Crit Care Med.* 2013;17(5):311–3.

Author biography

Manishi Shriwas, Assistant Professor  <https://orcid.org/0009-0009-4737-3844>

Dinesh Sharma, Assistant Director

Vaishali Sinha, Assistant Professor

Cite this article: Shriwas M, Sharma D, Sinha V. A rare cases of ferrous sulphate poisoning- A case study. *Indian J Forensic Community Med* 2023;10(3):129-131.