

Content available at: <https://www.ipinnovative.com/open-access-journals>

Indian Journal of Forensic and Community Medicine

Journal homepage: <https://www.ijfcm.org/>

Case Report

A meticulous autopsy halts erroneous justice – Case report

S Ramalingam^{1,*}, Veeravijayan A¹, Narayanan S²

¹Institute of Forensic Medicine, Madras Medical College, Chennai, Tamil Nadu, India

²Dept. of Forensic Medicine, Government Medical College, Thiruvallur, Tamil Nadu, India



ARTICLE INFO

Article history:

Received 31-03-2023

Accepted 17-04-2023

Available online 25-04-2023

Keywords:

Autopsy

Trauma

Disease

174 CrPC

IPC S304A

ABSTRACT

The relationship between the trauma and the disease poses a biggest problem in interpretation, when a person who was either previously diseased dies after a trauma or who developed disease after sustaining injury. The importance of an autopsy in establishing the actual cause of death is most important in natural deaths, but it is even more important in the event of unnatural deaths. Here, we present a case report where the investigating agency booked the case under IPC S.304A and later the cause of death in the case is found to be a natural and the section was altered to 174 CrPC.

This is an Open Access (OA) journal, and articles are distributed under the terms of the [Creative Commons Attribution-NonCommercial-ShareAlike 4.0 License](https://creativecommons.org/licenses/by-nc-sa/4.0/), which allows others to remix, tweak, and build upon the work non-commercially, as long as appropriate credit is given and the new creations are licensed under the identical terms.

For reprints contact: reprint@ipinnovative.com

1. Introduction

The importance of an autopsy in establishing the actual cause of death is most important in natural deaths, but it is even more important in the event of unnatural deaths. Often the cause of death looks quite obvious, especially in mechanical or regional injuries. But most of the times, it is little difficult to determine whether the natural disease caused the trauma or the trauma precipitated the underlying undiagnosed natural diseases particularly in an assault. If a wrong opinion is given, either a culprit can be acquitted or an innocent person can be sentenced. Wrong decisions or misjudgements are undesirable and dangerous in forensic medicine.¹ The co-relation between trauma and disease poses a problem in interpretation, when a person dies after experiencing trauma but has already had a disease, or who developed complications of the pre-existing disease after sustaining injury. Here we present a case report where the investigating agency booked the case under IPC S.304A and later the cause of death in the case is found to be a natural and the section was altered to 174 CrPC.

* Corresponding author.

E-mail address: ramssurgeon@gmail.com (S. Ramalingam).

2. Case History

A 78-year-old male was brought to a private hospital with the history of fall from two-wheeler who is a pillion rider with History of loss of consciousness following RTA on day 1, 6.00 p.m. On admission, patient was drowsy but arousable. BP was not recordable and GCS was E4 M6 V3. From the private hospital, he got discharged against Medical Advice and was brought to our Tertiary Care Hospital on the same day 11.20 P.M for treatment. In spite of the treatment, he died on the day 2, 12.10 a.m. (Within one hour of admission) and provisional cause of death made was – Seizure/Aspiration Pneumonitis/Respiratory Failure/Shock. The body was kept in mortuary.

This case was booked under S.304 A IPC in view of rash and negligent act of the driver. After getting post-mortem requisition letter from the investigating officer, autopsy was conducted. On autopsy, deceased was a moderately nourished and moderately built male; post-mortem hypostasis fixed on the back with areas of contact pallor; cornea – hazy; pupils - dilated and fixed.

The following ante mortem injuries was noted on the body:

1. Irregular dark red abrasions: a) 1 x 1 cm on the inner aspect of right foot (Figure 1); b) 0.5 x 0.5 cm on the front of upper third of left leg; c) 0.5 x 0.5 cm, 0.5 x 0.5 cm on the front of left knee (Figure 2)

No other external or internal injuries anywhere on the body .

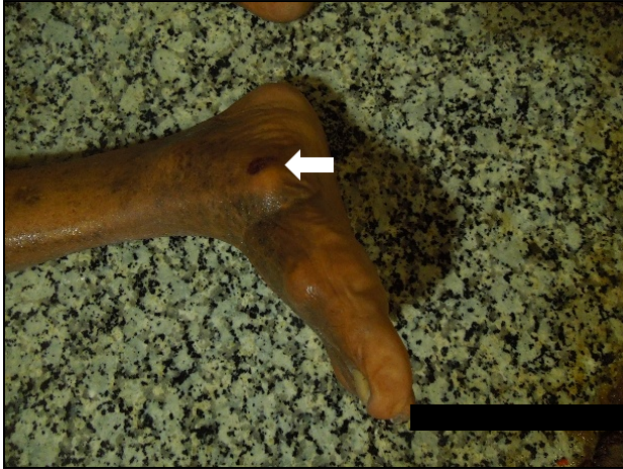

Fig. 1: Abrasion of right foot

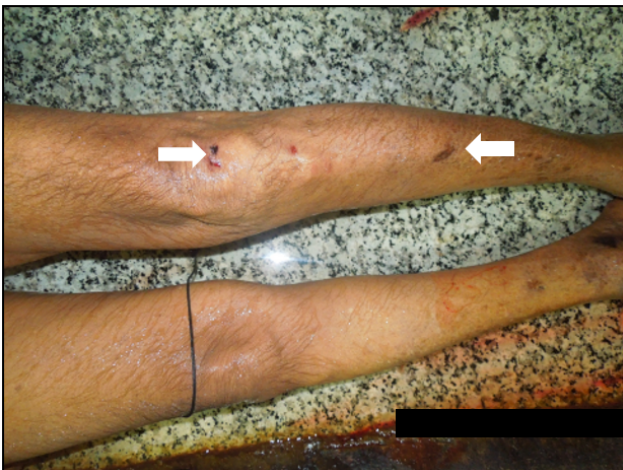

Fig. 2: Abrasions of left knee and leg

Pericardial cavity contained 110 grams of dark red clotted blood on the anterior and posterior surface of heart (Figures 3, 4 and 5). Heart: Enlarged in size; weighed – 460 grams; 1 cm full thickness rupture of the posterior wall of left ventricle involving papillary muscle with surrounding zone of hyperaemia 2 x 2 cm on the posterior wall of left ventricle close to interventricular septum (Figures 6 and 7); cut section: All chambers contained fluid and clotted blood; Left ventricle thickness: 2 cm (Figure 8) Valves: Thickened and calcified; Both the Coronary Ostia: Narrowed (Figure 9); Great vessels:

Multiple raised Atheromatous plaques on the inner surface of the root of Aorta; Circumferential, calcified and raised Atheromatous plaques on the inner surface of both the right and left coronary arteries (Figure 10).

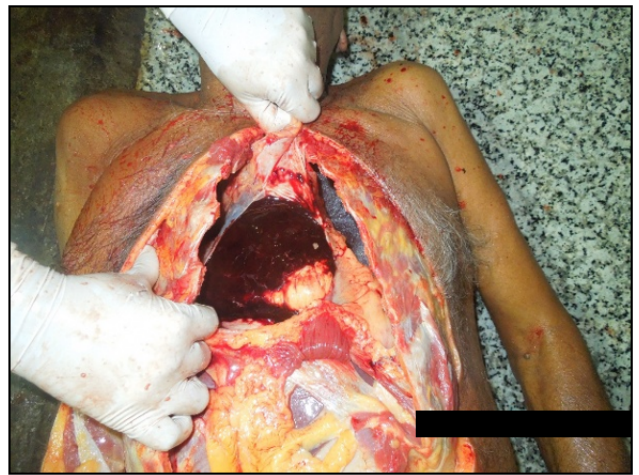


Fig. 3: Clotted blood in the pericardial sac

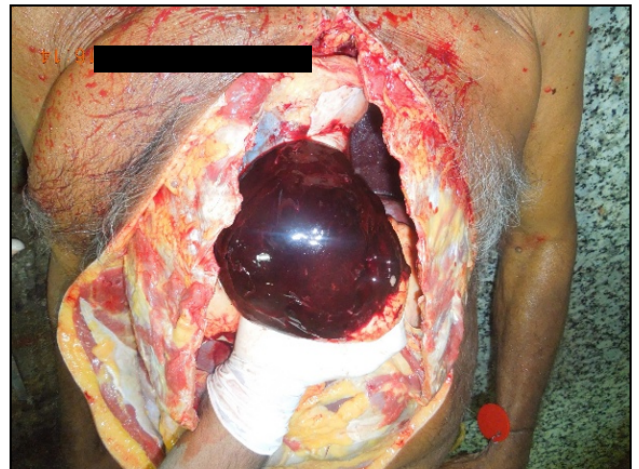

Fig. 4: Clotted blood on the anterior surface of the heart

Lungs: Normal in size; cut section: Congested

Larynx and Trachea: Empty and intact; Hyoid bone and other laryngeal cartilages: Intact; Multiple raised Atheromatous plaques on the inner surface of the blood vessels on both the sides of neck

Stomach: Contained 100 ml of coffee brown fluid with no definite smell; mucosa: Patchy areas of congestion

Liver, Spleen and Kidneys: Normal in size; cut section: Congested

Bladder: Empty and intact

Scalp, Vault, Duramater and Base of Skull: Intact; Brain: Normal in size; cut section: Normal; multiple raised Atheromatous plaques on the inner surface of the cerebral

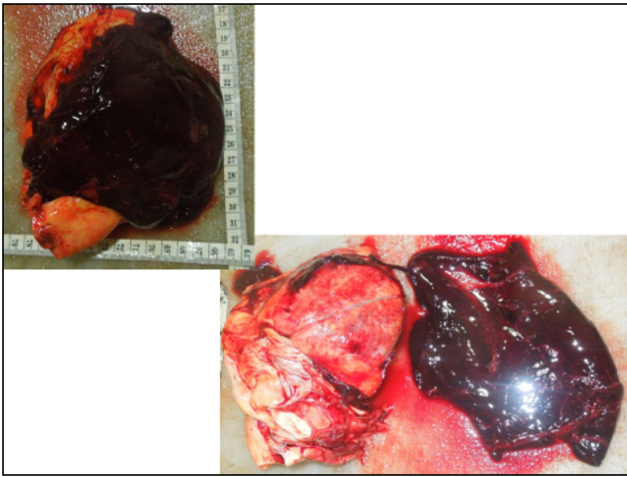


Fig. 5: Clotted blood on the anterior surface and posterior surface of the heart

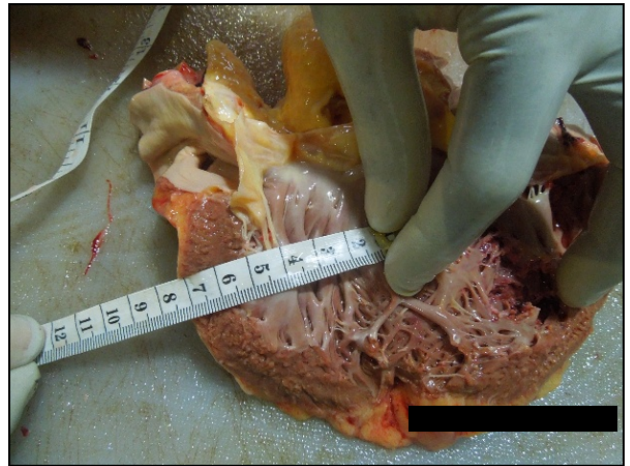


Fig. 8: Thickened wall of left ventricle

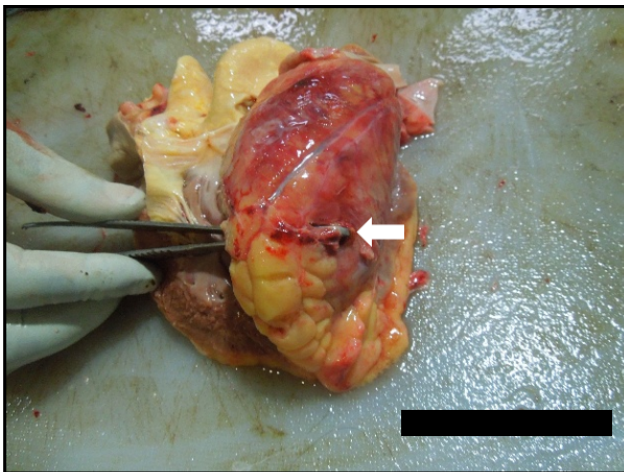


Fig. 6: Rupture of posterior wall of the left ventricle

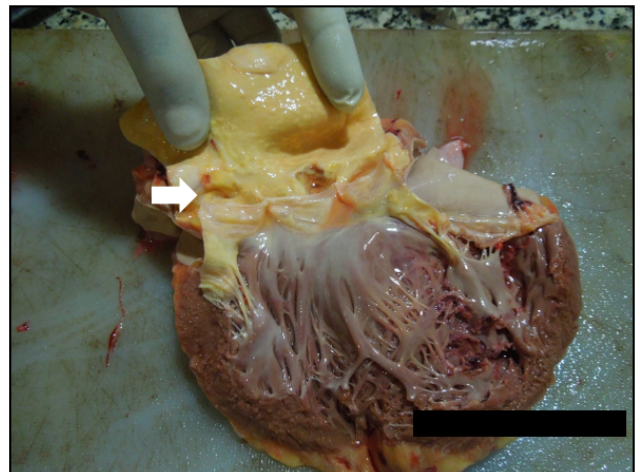


Fig. 9: Root of Aorta with narrowed Coronary Ostia

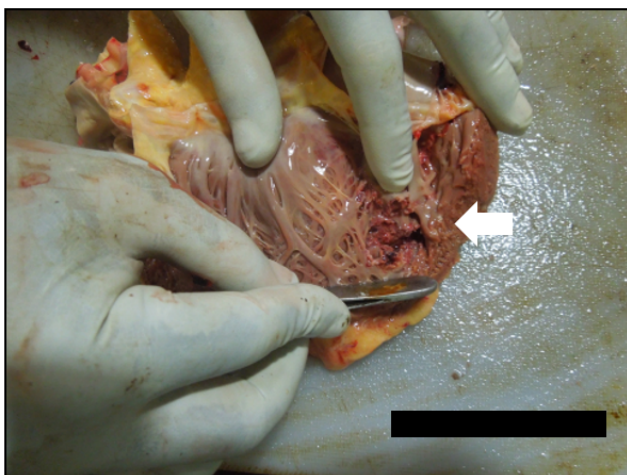


Fig. 7: Rupture of papillary muscle

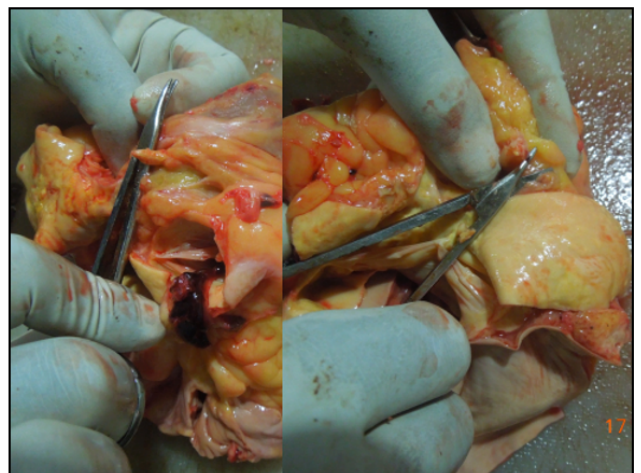


Fig. 10: Calcified left coronary artery

blood vessels in the region of Circle of Willis (Figure 11).

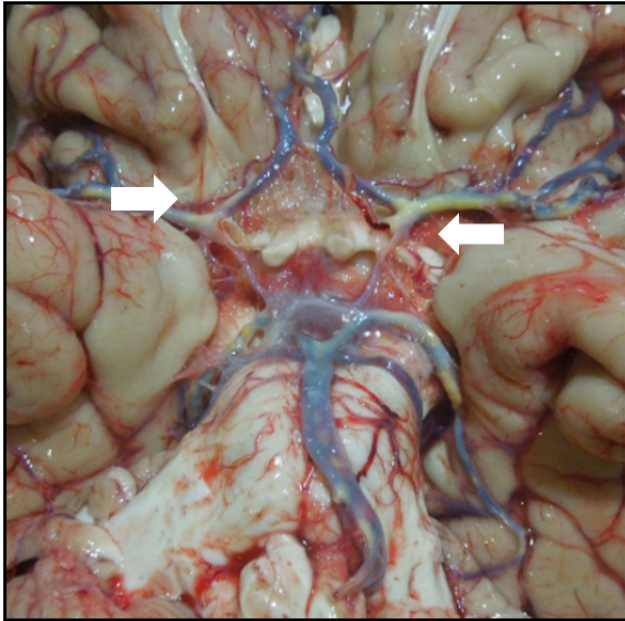


Fig. 11: Multiple raised atheromatous plaques in the circle of Willis

Ribs, Pelvis and Spinal column: Intact.

Viscera preserved for chemical analysis and tissue bits preserved for Histopathological examination.

Initial Opinion as to the cause of Death — Reserved pending the reports of chemical analysis of viscera and Histopathological examination of Tissue bits.

2.1. *Viscera report came as negative for Alcohol and/or Poison*

2.2. *HPE Report*

Heart: Muscle fibre with evidence of infarction and foci of haemorrhage with inflammatory infiltrates; (Figure 12)

Aorta: Blood vessel with intima showing foamy macrophages, cholesterol clefts and calcification. (Figure 13)

2.3. *Final opinion*

Final opinion as to the cause of death was given as the deceased would appear to have died of pericardial tamponade due to complications of Myocardial infarction (Natural cause).

3. Discussion

Trauma may predispose the victim to a natural disease or may aggravate an already existent natural disease.² The relationship between the trauma and the natural disease especially heart disease is always a difficult area of

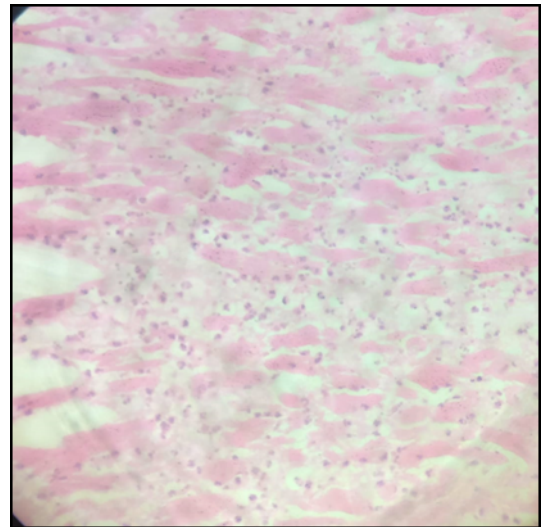


Fig. 12: HPE of heart muscle showing infarction and foci of haemorrhage with inflammatory infiltrates

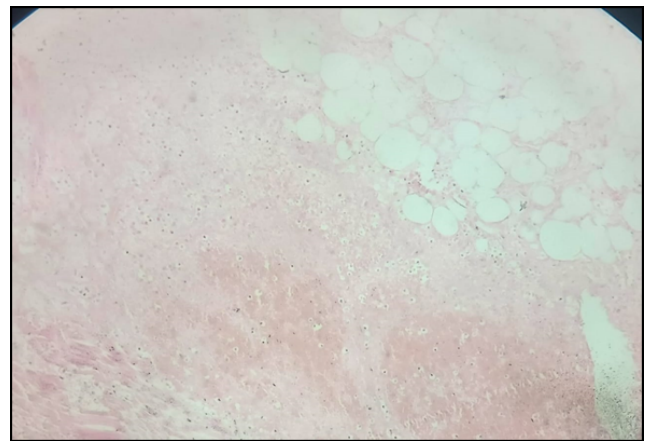


Fig. 13: Aorta showing foamy macrophages and cholesterol clefts

concern for forensic pathologist. A blow or some physical trauma may precipitate a myocardial infarct or arrhythmia. The emotional upset that accompanies injury, or even the threat of fear of an injury can cause death due to transient hypertension or tachycardia that may precipitate a subintimal haemorrhage, arrhythmias, or intracranial haemorrhages.³ A heart attack may occur while during quarrel either incidentally as a normal progression of a chronic disease process or due to unusual physical or mental strain. It is due to sudden release of epinephrine.³

The other areas to be concerned in this aspect are the bursting of an aneurysm, cerebral or subarachnoid haemorrhage, hypertension or any other natural disease. Death may occur from a slight injury inflicted on previously diseased organ, e.g., miliary aneurysms, fatty degeneration of heart, duodenal ulcer, ulcerative colitis, enlarged spleen especially due to malaria, amoebic liver abscess, hydatid

cyst, tuberculosis, disseminated sclerosis, parkinsonism, etc. Dissemination of a neoplasm might be accelerated by direct injury.

In the court of law, a causal relation is established if that particular trauma aggravates, hastens or precipitates a disease of a person. It is not necessary that trauma be an etiologic cause. In such cases, if injury accelerates the process of dying or precipitates death, the assailant is not guilty of culpable homicide, but he can be charged of simple or grievous hurt, if it can be proved.^{2,3} It is also predictable that these persons could have succumbed to his pre-existing heart disease at any moment.⁴ If it can be proved from an autopsy that death resulted from natural cause, and that the infliction of the injury did not operate in any way either immediately or remotely, the assailant will not hold responsible for the death of his victim. In these cases, death might have taken place about the same time and in the same circumstances whether there was quarrel or not.²

In forensic literature, sudden death of a man resulting from exacerbation of pre-existing heart disease that is induced by physical and/or emotional stress of a criminal activity of another person is sometimes referred to as —homicide by heart attack.⁵

Sahipaul RL et al. reported a case of rupture of a left vertebral artery berry aneurysm in a 34-year-old man following trauma over left mastoid area by a hockey puck. A massive subarachnoid hemorrhage in the posterior fossa and the remnants of a berry aneurysm in the left vertebral artery were found during the autopsy.⁶

Anand. P. Rayamane et al. also published a case series with four cases where the investigating officer registered the cases under IPC S.304A or 302 but the death was due to natural disease such as CAD, CVD (Coronary Artery Disease, Cerebro Vascular Disease) and rupture of enlarged spleen.⁷

4. Conclusion

In court of law the defense counsellor often takes the plea of natural disease as cause of death or injury as contributory factor or injury aggravates disease process leading to death. So as a forensic expert one should be careful in giving such opinion and before opine, evaluate medical history,

thorough autopsy findings, histopathology and chemical analysis report.

Not all the cases registered under IPC S.302 are homicide. Sometimes the natural disease may be the killer. A thorough and meticulous autopsy usually solve the mysteries in such scenarios.

5. Source of Funding

None.

6. Conflict of Interest

None.

References

1. Banwari M. An erroneous opinion on a cause of death in a forensic autopsy: a case report. *Afr Health Sci.* 2017;17(4):1246–49.
2. Aggrawal A. Textbook of Forensic Medicine and Toxicology. 2nd ed. Himachal Pradesh: Avichal Publishing Company; 2021. p. 226–31.
3. Reddy KSN. Medicolegal aspects of wounds. In: The Essentials of Forensic Medicine and Toxicology. Jaypee Brothers Medical Publishers(p) Ltd; 2022. p. 238–41.
4. Huikuri HV, Castellanos A, Myerburg RJ. Sudden death due to cardiac arrhythmias. *N Engl J Med.* 2001;345(20):1473–82.
5. Turner SA, Barnard JJ, Spotswood SD, Prahlow JA. Homicide by heart attack” revisited. *J Forensic Sci.* 2004;49(3):598–600.
6. Sahjpaul RL, Abdulhak MM, Drake CG, Hammond RR. Fatal traumatic vertebral artery aneurysm rupture: Case report. *J Neurosurg.* 1998;89(5):822–4.
7. Rayamane AP, Patra AP, Kumar M, Chandrashekaraiiah C, Sushma TA, Mahanthacar V. Trauma and Disease- Medicolegal implications; 2013.

Author biography

S Ramalingam, Associate Professor  <https://orcid.org/0000-0001-5971-3070>

Veeravijayan A, Tutor

Narayanan S, Assistant Professor

Cite this article: Ramalingam S, Veeravijayan A, Narayanan S. A meticulous autopsy halts erroneous justice – Case report. *Indian J Forensic Community Med* 2023;10(1):52-56.