

Study of incidence of histopathological changes in liver due to agricultural poisons – a prospective study conducted at Govt. Stanley Medical College, Chennai

S. Balasubramanian¹, A. Gokulakrishnan^{2,*}

¹Associate Professor, ²Assistant Professor, Dept. of Forensic Medicine, Govt. Stanley Medical College, Chennai

***Corresponding Author:**

Email: janyraj@gmail.com

Abstract

A two year prospective study was conducted from May 2014 to May 2016 a total of 4123 autopsies were conducted amongst 906 cases with the history of agricultural poisoning were studied. In that 535 cases were females and 371 cases were male. Age of the individuals varied from 7 years to 65 years. Amongst 80% of cases was in the age group of 25 to 35 years. Most of the cases are suicidal in nature and 2% are accidental in nature. In 643 cases poisons were confirmed by chemical analysis of state forensic science laboratory, in that 368 cases were organ phosphorus compound, 97 cases were aluminium phosphide and 81 cases were zinc phosphide, 97 cases are Pyrethrin compounds and in remaining cases poison was not detected by chemical analysis. In all cases liver was examined for both gross and histological changes, most cases showed severe congestion by gross examination. Histological changes in liver were classified based on the degree of damage to hepatic tissue caused by agricultural poisonous substance were grouped into I, II & III. Group I include Congestion, sinusoidal dilatation, mononuclear and neutrophilic infiltration, group II include Cytoplasmic vacuolization and hydropic degeneration, group III include Patchy or centrilobular necrosis and patchy haemorrhages. Based on duration of treatment amongst poisoning cases study group was classified. In that 653 cases were treated for less than 24 hr, 174 cases were treated for 2 – 5 days, 79 cases were treated for 5 – 10 days. In the present study organophosphorus compound was most commonly used and female victims in middle age group were predominant and the histopathological findings were grouped based on the degree of damage to the hepatic tissue and there incidence were identified based on type of agricultural poison and duration of treatment. Group I histological changes were predominantly seen among organophosphorus compound and the persons who were treated less than one day, group II & III changes were predominant among phosphates, Pyrethrin compounds and the persons who were treated more than two to five days.

Keywords: Agricultural poisons, Organophosphorus compounds, Phosphates, and Pyrethrin.

Introduction

Acute poisoning by Pesticide compounds is a major global clinical problem, with thousands of deaths occurring every year. Most of these pesticide poisoning and subsequent deaths occur following an intentional self-ingestion of the poison.⁽¹⁾ The potential adverse impact on human health from pesticides exposure is likely to be higher due to easy availability of highly hazardous products.

It has been estimated that pesticides were directly or indirectly is responsible for more than 1 million illnesses worldwide annually, and this figure could be just the tip of the iceberg since most cases of poisoning actually go unreported, due to Inadequate Poison Information Centres, Forensic laboratories, and lack of knowledge in utilizing the pesticides, toxicological studies.⁽²⁾

In developing countries like India major source of human poisoning is through agricultural poisons. The problem is getting worse with time as newer drugs and chemicals are developed in vast numbers. The commonest pesticides agents in India appear to be organophosphates, carbamates, pyrethroids and aluminium/zinc phosphide.

After ingestion, most of the poisons are rapidly absorbed throughout the gastrointestinal tract and it is carried to the liver by the portal vein for metabolism

and excretion. It is known that most of the compounds are toxic to liver can cause liver dysfunction. However, there are limited studies about the gross and histopathological changes in liver in autopsy. So we conducted the present study to find out incidence of histological changes in liver due to agricultural poisons.

Materials and Methods

A two year prospective study on incidence of histopathological changes in liver due to agricultural poisoning cases were studied amongst autopsies conducted at government Stanley medical college from May 2014 to May 2016.

A detailed history was taken from inquest report and from relatives in all cases type of exposure, manner of death and treatment history were taken from hospital case records. Further, type of poison was confirmed by toxicological evaluation reports. During Autopsy detailed internal and external examinations were done and random portion of Liver were collected for histological examination and fixed in 10% formalin and stained with Hematoxylin and eosin and the findings recorded. Histological features were grouped based on degree of damage to hepatic tissue. (Table 3)

In the present study decomposed bodies, death due to other disease condition and cases with the history of chronic alcohol intake, hepatitis, poisoning due to other

than agricultural poisonous compounds were excluded from the study.

Results

In the present study, a total of 4123 autopsies were conducted. Of the total, 906 cases with the history of poisoning were studied in that 535 cases were females and 371 cases were male.

Age of the individuals varied from 7 years to 65 years amongst 80% of cases was in the age group of 25 to 35 years. (Table 1)

Table 1: Shows no of cases with particular age groups

Age group	No of cases
7 -25 years	256
25 -35 years	467
35 – 65 years	183

98% of the cases were suicidal in nature and 2% were accidental in nature.

Of 906 cases in 643 cases poisons were confirmed by chemical analysis of state forensic science laboratory, in that 368 cases were organo phosphorus compound, 97 cases were aluminium phosphide and 81 cases were zinc phosphide, 97 cases were Pyrethrin compounds and in remaining cases poison was not detected by chemical analysis (Table 2).

Table 2: Shows no of cases detected by chemical analysis

Type of poison detected by chemical analysis	No of cases
Organ phosphorus compounds	368
Aluminium and zinc phosphates	178(97+81)
Pyrethrin compounds	97
Unknown / not detected by chemical analysis	263

In all cases liver was examined for both gross and histological changes, most cases showed severe congestion by gross examination.

Histological changes in liver were classified based on the degree of damage to hepatic tissue caused by agricultural poisonous substance were grouped into I, II & III.

Group I include Congestion, sinusoidal dilatation, mononuclear and neutrophilic infiltration, group II include Cytoplasmic vacuolization and hydropic degeneration, group III include Patchy or centrilobular necrosis and patchy haemorrhages. (Table 3)

Table 3: Shows histological classification

Histological classification	Histological features
Group I	Congestion, sinusoidal dilatation, mononuclear and neutrophilic infiltration.
Group II	Nuclear fragmentation, Cytoplasmic vacuolization and hydropic degeneration.
Group III	Patchy or Centrilobular necrosis and patchy haemorrhages

Of 906 cases 368 were organophosphorus compound in that Congestion, sinusoidal dilatation, mononuclear and neutrophilic infiltration (Group I) were predominantly seen. 178 cases are phosphide compounds in that Cytoplasmic vacuolization, hydropic degeneration, Patchy or centrilobular necrosis and patchy haemorrhages (group II & III) were predominant. In 97 cases of Pyrethrin compound group I & II changes were predominantly, in remaining unidentified poison cases mixed feature was observed. (Table 4)

Table 4: Shows types of poisons detected by chemical analysis and there histological changes

Type of poison detected by chemical analysis	No of cases	Histological changes noted
Organ phosphorus compounds	368	Group I
Aluminium and zinc phosphates	178	Group II & III
Pyrethrin compounds	97	Group I, II
Unknown / not detected by chemical analysis	263	Group I, II & III

In the present study based on duration of treatment amongst poisoning cases study group was classified in that 653 cases were treated for less than 24 hr, 174 cases were treated for 2 – 5 days, 79 cases were treated for 5 – 10 days.

Amongst 906 cases, 603 cases were hospitalized for 0 – 1 day. In that group I histological feature were predominantly seen, 174 cases were hospitalized for 2-5 days; in that group II changes were predominant, 129 cases were hospitalized for 5- 10 days; in that group III changes were seen. (Table 5)

Table 5: Shows no of days treated and there histological changes

No of cases	No of days treated	Histological changes (> 90%)
603	0-1 days	Group I
174	2- 5 days	Group II
129	5- 10 days	Group III

Discussion

The incidence of poisoning cases in India is highest in the world, and it is estimated that more than 50,000 people die every year from toxic exposure.⁽³⁾ The common agents causing poisoning in India appear to be pesticides (organophosphorus, organochlorine, carbamates, pyrethroids). Of 906 cases, 535 cases were females and 371 cases were male. In the present study, females (59.3%) outnumbered males (40.7%) and deaths were more among married group. This is comparable with other studies, and shows that married persons may become victims of greater stress than single individuals in their day-to-day lives. The different causes of the stress culminating in poisoning ranged widely from marital and family discords to financial and job related problems to educational and other matters.⁽⁴⁾

In 906 cases, 467 cases were in the age of 25 -35 years. The distribution pattern among particular age group illustrates the psychological vulnerability in this age group. Similar patterns have been reported in a number of other studies. In a similar study conducted by Saha S et al on changes in liver in case of insecticidal and alcohol poisoning: an autopsy study revealed most common age group affected in this study is between 20-40 years.

Suicide was the most common mode of poisoning in this study. Among agricultural poisons organophosphorus compound was the most common type of poison consumed. Studies from other regions from India have also reported organophosphates as common causes of poisoning due to easy availability in the market leads to more number of poisoning cases.⁽²⁾

In most cases poisonous compound was undetected due to prolonged treatment, poisons were metabolized and excreted from the body, and lack of collecting stomach wash contents at casualty makes most of the poisons undetected.

Liver is the organ where bio-activation and detoxification of poisonous compounds takes place. However, many studies have been conducted in past on animals and humans to assess the effect of different types of pesticides on the histology of cells and tissues. In present study we found several histopathological changes in victims of fatal pesticide poisoning and the findings were grouped based on degree of damage to the liver tissue (Table 3).

In 368 cases of organo phosphorus compound poisoning group I histopathological changes were predominant. Organophosphates act as irreversible cholinesterase inhibitors. The inhibition of cholinesterase activity leads to the accumulation of acetylcholine at synapses, causing overstimulation and subsequent disruption of transmission in both the central and peripheral nervous systems.⁽⁵⁾ This leads to hyper secretion and paralysis of respiratory muscles. Liver is the organ where bio activation and detoxification of OP compounds takes place. But they

are eliminated primarily through kidneys⁽⁶⁾ and there is a minimal injury to the hepatic tissue.

Group 2 and 3 changes were predominant in phosphates and Pyrethrin compound poisoning due to direct action of poison in liver leads to inhibition of cytochrome C oxidase and subsequent generation of reactive oxygen species causes hydropic degeneration and Centrilobular necrosis.⁽⁷⁾ Similar findings were seen in other studies like S Sutay et al on pattern of Histo-pathological changes of liver in poisoning. In that organophosphorus was the poison used most commonly. According to the author congestion was seen in 20 (46.5%) and fatty changes in 15 (34.9%) cases; centrilobular necrosis in 4 (9.3%), and Sinusoidal dilatation in 3 (7.0%) cases

In a study conducted by M Kumar et al on pesticide poisoning, common microscopic finding were portal and sinusoidal congestion (60%), microvacuolization (52%), hydropic degeneration (44%) and mononuclear infiltration (48%), micro & macro-vesicular steatosis (44%).⁽⁸⁾

In a study conducted by S Saleki et al on histopathological changes on fatal phosphine poisoning, the most frequent histopathological findings have been sinusoidal congestion and fine cytoplasmic vacuolization of hepatocytes. The fine cytoplasmic vacuoles which were the most consistent finding in our cases are rather uniform in size and shape. The vacuoles were distributed uniformly in all acinar zones in the majority (71.1%) of cases. Other less frequent histopathological findings include portal oedema, portal vein congestion, central vein congestion, centrilobular necrosis, nuclear fragmentation, clusters of polymorphonuclear leukocytes in sinusoids macro vesicular steatosis, and sub capsular haemorrhage.

In a study conducted by Karki R K et al on study of poisoning cases in tertiary care hospital showed there were 137 cases during the one year duration and maximum case belonged to second and third decade of life. Most common manner of poisoning was suicidal and the incidence was mainly during evening hours. Organophosphorus was the most commonly abused substance.⁽⁹⁾

Interesting feature observed in the present study was the histological changes in the liver vary based on duration of treatment in most of the group I changes were predominant amongst cases were treated less than one day, group II were predominant if they treated up to five days, if more than five days group III were predominant. In a study conducted by Jarzouna in 2010 on impact of dieldrin on liver morphological and biochemical parameters on the liver of Wistar rats. The dieldrin effect on rats was tested after a single intraperitoneal injection of two doses: 3 and 6 mg/kg and observations were made 4 days later. Histological examination of the liver of dieldrin-treated animals revealed Cytoplasmic vacuolation, focal necrosis and nuclear enlargement of hepatocytes.⁽¹⁰⁾

Conclusion

In the present study organophosphorus compound was most commonly used and female victims in middle age group were predominant and the histopathological findings were grouped based on the degree of damage to the hepatic tissue and their incidence were identified based on type of agricultural poison and duration of treatment

Group I histological changes were predominantly seen among organophosphorus compound and the persons who are treated less than one day, group II & III changes were predominant among phosphates, Pyrethrin compounds and the persons who were treated more than two to five days.

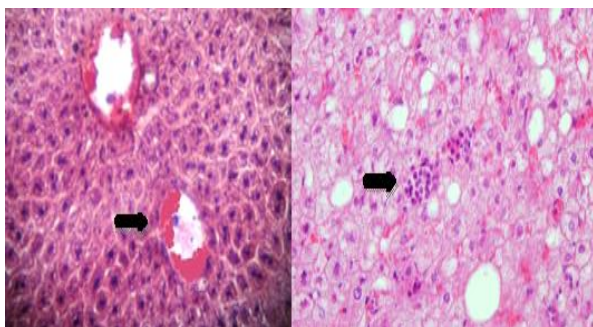


Fig. 1(a & b): Shows group I changes, 1a shows congestion and sinusoidal dilatation, 1b shows monocytes and neutrophilic infiltration

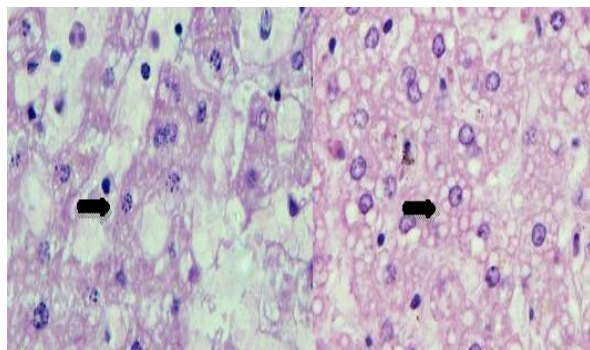


Fig. 2(a & b): Shows group II changes, 2a shows nuclear fragmentation, 2b shows fine Cytoplasmic vacuolation

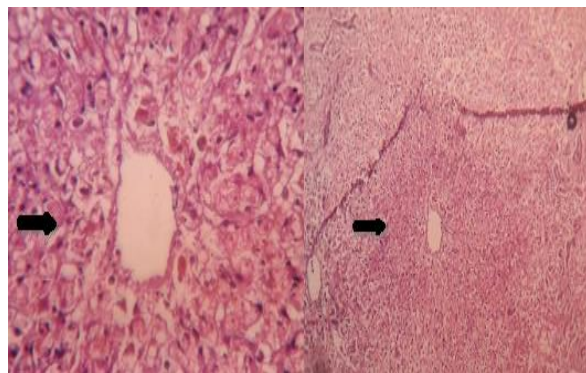


Fig. 3(a & b): Group 3 changes, 3a shows centrilobular necrosis, 3b shows patchy haemorrhages at places

References

1. Clinical Management of Acute Pesticide Intoxication: Prevention of Suicidal Behaviours. p-9. Available from www.who.int/mental_health/prevention/suicide/pesticides_intoxication.pdf last accessed on 07/7/2016.
2. Subash V k, Md. Fareedullah Current review on organophosphorus poisoning. Archives of Applied Science Research.2010;2(4):199-215.
3. Pillay VV. The utility of poison control centres in diagnosing and managing cases of poisoning and overdose. J Indian Acad Forensic Med.2010;108(3):162-66.
4. Senanayake N, Petris H. Mortality due to Poisoning in a Developing and Agricultural Country- Trends over 20 years. Hum Exp Toxicology. 1995;14:808-811.
5. Vale JA. Toxicokinetic and toxicodynamic aspects of organophosphorus (OP) insecticide poisoning. Toxicol lett. 1998;102-103:649-652.
6. Barr DB, Allen R, Olsson AO, Bravo R, Caltabiano LM, Montesano A, et al. Concentrations of selective metabolites of organophosphorus pesticides in the United States population. Environ Res. 2005;99:314-26.
7. Sepideh S, Farid A. Liver histopathology of fatal phosphine poisoning Forensic Science International. 2007;166:190-193.
8. Manish K N, Bhawna B. Pesticide poisoning – an epidemiological and histopathological study. Pacific Journal of Medical Sciences.2013; Vol. 12.
9. Karki RK, Risal A. Study of Poisoning Cases in a Tertiary Care Hospital. Kathmandu Univ Med J 2012;10(4):70-73.
10. Subhasish S, Dipkana D. Changes in liver in case of insecticidal and alcohol poisoning: an autopsy study. Journal of Evolution of Medical and Dental Sciences. 2015; Vol. 4, Issue 27, April 02; Page: 4622-4628.