

## A study on medico-legal and clinical aspects of congenital sternal foramina

Sandesh H Chaudhari<sup>1,\*</sup>, Naresh Kumar<sup>2</sup>, Gourav Thakre<sup>3</sup>, Harshal Kawanpure<sup>4</sup>, Bhupendra Gathe<sup>5</sup>

<sup>1,4</sup>Associate Professor, <sup>2,3,5</sup>Assistant Professor, Chandulal Chandrakar Memorial Medical College, Chhattisgarh

**\*Corresponding Author:**

Email: dr.sandeshchaudhari@yahoo.com

### Abstract

Sternal foramen is a congenital round bony defect present in the body of sternum which results from incomplete union of the sternal ossification centres. Usually the defect is asymptomatic and only be detected by CT scan. But at times, it may be misinterpreted as gun shot or stab wound. In clinical practice, sudden unexpected death may take place during sternal puncture and biopsy as a result of cardiac puncture and tamponade. The present study was carried out by choosing 96 dry sternal bones which were used as a teaching material in the Department of Forensic medicine and Anatomy, CCM Medical College, Durg, Chhattisgarh and MIMER Medical College, Talegaon, Pune, Maharashtra. These sternal bones were examined for the presence of sternal foramen and it was found in 4.1% of cases. It is important for medical practitioners, radiologists and acupuncturists to have a concrete knowledge of sternal anomalies before doing any procedures to avoid complications.

**Keywords:** Sternum, Foramen, Autopsy, Congenital anomaly, Cardiac tamponade.

### Access this article online

#### Website:

www.innovativepublication.com

#### DOI:

10.5958/2394-6776.2016.00043.6

### Introduction

The sternum is among the skeleton parts with variation in appearances on images or during autopsy studies. In human, sternal variations and anomalies are incidentally detected by radiological procedures. The sternal foramen is usually asymptomatic and not visible on plane radiograph. It is visible only on CT scan<sup>3</sup>. Multiplanar and 3D reconstructed multidetector CT (MDCT) images are the investigation of choices for diagnosis of sternal foramen<sup>17</sup>. Knowledge of sternal variations and anomalies is beneficial so as to differentiate those with pathological conditions and acquired lesions<sup>1,14</sup>. Sternal foramen is a round or oval congenital bony defect which results from incomplete union of the ossification centres. It is a rare congenital anomaly and presence of it may mislead in evaluation of skeletal remains<sup>2,14</sup>. The knowledge of the anomaly is important in acupuncture procedure because of the damage to the heart and great vessels<sup>3,14</sup>. It is also one of the risk factor during bone marrow biopsy which

may lead to cardiac tamponade<sup>18</sup>. Incidence of sternal foramen and its significance in medico-legal cases is poorly reported in the literature. Hence we emphasis to carry out this study to spread awareness of the anomaly and minimize the complications arising out of sternal defect.

### Materials and Methods

Study was carried out choosing randomly collected 96 dry sternal bones which were used as a teaching material in the Department of Forensic medicine and Anatomy, CCM Medical College, Durg, Chhattisgarh and MIMER Medical College, Talegaon, Pune, Maharashtra. These sternal bones were examined and reviewed for the existence of sternal foramen. Sex determination of the bones was not done.

### Result

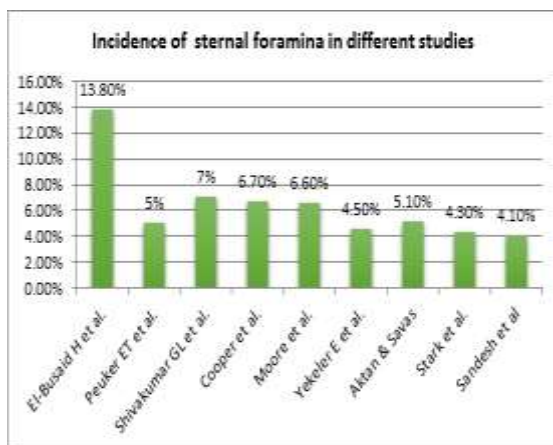
The sternal foramina were found in the lower one third part of sternunal body, as a single midline oval or round defect. (Fig. 2, 3, 4 & 5). The size of sternal foramina ranged between 3 mm and 10 mm (Table 1). The measurement of size of the foramina is done using digital caliper. Total number of sternal bones having sternal foramen was found to be 4 out of the 96 bones examined. So the total percentage of sternal foramina in our study is found to be 4.1%.

**Table 1: Measurement of sternal foramina**

Dimensions	Sternal foramen 1	Sternal foramen 2	Sternal foramen 3	Sternal foramen 4	Average
Transverse diameter	9 mm	5 mm	4 mm	10 mm	7 mm
Vertical diameter	7 mm	4 mm	3 mm	8 mm	5.5 mm

**Table 2: Incidence of sternal foramina in different studies**

Different studies	Incidence of sternal foramina
El-Busaid H et al.	13.8%
Peuker ET et al.	5-8%
Shivakumar GL et al.	7%
Cooper et al.	6.7%
Moore et al.	6.6%
Yekeler E et al.	4.5%
Aktan & Savas	5.1%
Stark et al.	4.3%



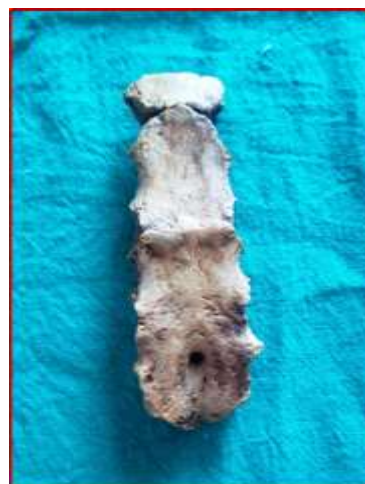**Fig. 1**



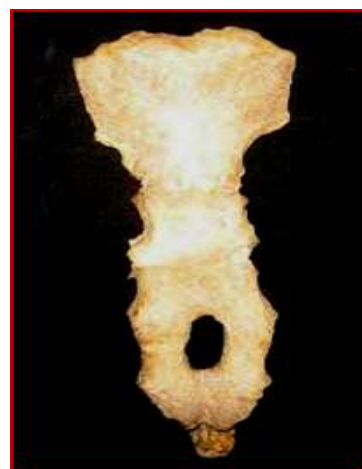**Fig. 2**



**Fig. 3**



**Fig. 4**



**Fig. 5**  
**Sternal Foramina**

**Discussion**

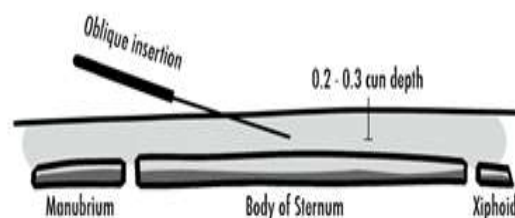
Sternum is a flat bone present in the anterior wall of the chest in the midline. It is about 17cm long in adult males, a little less in females. Sternum has three

parts i.e. manubrium (upper quadrangular part), body of sternum or gladiolus, (middle longest part) and xiphoid process or xiphisternum (terminal part)<sup>18</sup>. The sternum is a mesodermal in origin. The bone is formed by bilateral condensations of mesenchymatous tissue, called as 'sternal bars' which are initially present on both sides of chest wall. These bars migrate and converge towards middle during 8<sup>th</sup> week of gestation to form 'sternal plate'. Fusion gets completed by 10<sup>th</sup> week in cranio-caudal direction<sup>18</sup>. After maturation into cartilage, it undergoes a series of transverse divisions into six cartilaginous segments known as 'sternebrae' or 'segments' (i.e. segment 1 to segment 6). The sternum ossify gradually from cartilaginous precursors and ossification occur by 6 ossification centres i.e. 1 for manubrium, 4 for body and 1 for xiphisternum. Manubrium is ossified from its center in the 5<sup>th</sup> fetal month. 1<sup>st</sup> & 2<sup>nd</sup> sternebrae ossify from single center at about same time (i.e. 5<sup>th</sup> month). 4<sup>th</sup> & 5<sup>th</sup> centers (3<sup>rd</sup> & 4<sup>th</sup> sternebrae) are usually paired and appeared in 5<sup>th</sup> and 6<sup>th</sup> months respectively. Xiphoid process begins to ossify in 3<sup>rd</sup> year or later. Union between mesosternal centres begins at adolescent and proceeds from below upward, by the age 25 years they all are fused<sup>17</sup>. Any failure in the development process results in various sternal anomalies such as fissures or foramen<sup>1,14</sup>. Apart from these sternal defects to be reported as complete midline sternal cleft, hybrid defect like key hole shaped deformity and & multiple sternal foramina<sup>18</sup>. Sternal foramen in the body is more common than that in manubrium and xiphisternum and more often located in lower third part of corpus sterni that results from incomplete fusion of sternal ossification centres<sup>1,6,7,18</sup>. Size of sternal foramen varies from 2 mm to 16 mm (mean is 6.5 mm)<sup>5</sup>

The incidence of sternal foramen was evaluated as 4.3% on chest CT by Stark<sup>8</sup>, 6.7% in autopsy cases by Cooper et al<sup>6</sup>, 6.6% by Moore et al<sup>7</sup>, Atkan & Savas<sup>9</sup> observed it in 5.1% in Turkish population and Yekeler E et al<sup>5</sup> found it in 4.5% cases.

In our present study, we observed defect in 4.1% which is near to the results found in a study by Stark et al<sup>8</sup>. (4.3%) Indian study by Shivakumar GL et al<sup>1</sup> reported 7% and Peuker ET et al<sup>10</sup> mentioned existence of sternal foramen in about 5% to 8% of population from his literature supported by post mortem anatomical observation which is twice the result of our study.

In a recent study done by El-Busaid H et al<sup>11</sup>. 13.8% of foramina were observed in Kenyan population, which shows higher frequency than in other population. Only Babinski et al<sup>15</sup>. reported highest prevalence of defect in 16.6%.



**Fig. 6: Correct method of sternal puncture**

### Clinical & Medicolegal Significance

Sternum is one of the bones chosen for bone marrow aspiration (the other site being the posterior part of the iliac bone). Clinical importance of the defect lies in the fact that cardiac tamponade and injury to great vessels may occur during improper needling for bone marrow aspiration<sup>18</sup>. Another importance of the sternum is that acupuncture point CV-17 (sea of energy) is located at the level of nipples in the midline. So vertical insertion of acupuncture needle can lead to pericardial effusion followed by cardiac tamponade<sup>17,18</sup>. Thus these procedures may raise medico-legal issues in future.

Regarding forensic aspect, during autopsy the sternal foramen may be misinterpreted as a gunshot injury. But the meticulous examination may distinguish between the two. The sternal foramen is having smooth, regular margins & covered with cortical bone. In bullet injury, there would be beveling & fracture line and absence of cortical bone at edges. Sometimes, bones exposed to insects or animals may have teeth or claw marks or erosions close to foramen which should not be mistaken for antemortem injuries.

The misinterpretation of such defects in medico-legal cases may lead to ambiguous conclusions in determining nature and cause of suspicious deaths.

### Conclusion

Sternal foramen is a minor anomaly yet leads to major clinical & medico-legal issues. It has got following significance.

1. May be helpful in personal identification of individual.
2. Radiographs may be confused with bullet wound or may misdiagnose for osteolytic change<sup>1</sup>.
3. It may be confused with the superimposition of necklace or a congenital anomaly<sup>13</sup>.
4. There is a potential risk of life threatening complications like pneumothorax, pericardial puncture or cardiac tamponade if needle is not inserted properly through the defect during sternal biopsy and in acupuncture techniques<sup>16</sup>.

So whenever the sternal puncture is planned, following precautions must be taken.

1. Prior radiographs must be obtained to rule out the defect to prevent fatal complications. Multiplanar & MDCT are the imaging of choices for detecting sternal anomalies<sup>17</sup>.
2. An oblique insertion of needle is recommended. However, in lean person having skin-heart distance of 1-2 cm, even a correct needling may lead to pericardial puncture<sup>18</sup>.
3. The depth from skin to pericardium varies considerably from 3-9.1 cm. If the needle is inserted not deeper than 2.5 cm, pericardial puncture would not have occurred<sup>16</sup>.

So, the sound knowledge of sternal variations & anomalies is very important for medical practitioners not only for medico-legal purpose but for better clinical outcome.

## References

1. Shiva kumar GL, Deepa G, Kadlimatti HS. Variations in the Human Sterna. *J Evol Med Dent Sci*2013;2(2):99-104.
2. Taylor HL. The sternal foramen: the possible forensic misinterpretation of an anatomical abnormality. *J Forensic Sci.* 1974;19:730-734.
3. Philip P, Michel De M, Kristoff M, Michel O. Sternal Foramen Simulating Osteolytic Lesion on Scintigraphy and SPET Imaging. *Ann Nucl Med Sci.*2002;15(4):227-230.
4. Standring S. *Gray's Anatomy, The Anatomical Basis of clinical practice.* 40th ed. China: Churchill Livingstone Elsevier, an imprint of Elsevier; 2008. Chapter 54, Chest wall and breast; p.917-918.
5. Yekeler E, Tunaci M, Tunaci A, Dursun M, Acunas G. Frequency of sternal variations and anomalies evaluated by MDCT. *Am J Roentgenol.* 2006;186:956-960.
6. Cooper PD, Stewart JH, McCormick WF. Development and morphology of the sternal foramen. *Am J Forensic Med Pathol*1988;9:342-347.
7. Moore MK, Stewart JH, McCormick WF. Anomalies of the human chest plate area: radiographic findings in a large autopsy population. *Am Forensic Med Pathol* 1988;9:348-354.
8. Stark P. Midline sternal foramen CT demonstration. *Comput Assist Tomogr* 1905;9:489- 490.
9. Aktan ZA, Savas R. Anatomic and HRCT demonstration of midline sternal foramina. *Turk J Med Sci.* 1998;28:511-514.
10. Peuker ET, White A, Ernst E, Pera F, Filler TJ. Traumatic Complications of Acupuncture Therapists Need to Know Human Anatomy. *Arch Fam Med.*1999;8:553-558.
11. El-Busaid H, Kaisha W, Hassanali J, Hassan S, Ogeng'o J, Mandela P. Sternal foramina and variant xiphoid morphology in a Kenyan population. *Folia Morphol (Warsz).*2012;71(1):19-22.
12. Schratte M, Bijak M, Nissel H, Gruber I, Schratte-Sehn AU. The foramen sternale: a minor anomaly great relevance. *Rofo.* 1997;166:69-71.
13. Pevenage P, Maeseneer MD, Muylle K, Osteaux M. Sternal Foramen Simulating Osteolytic Lesion on Scintigraphy and SPET Imaging. *Ann Nucl Med Sci.*2002;15:227-230.
14. A study of sternal foramina and its medico-legal importance. Ajay Kumar S, Daksha Dixit. *International Journal of Medical Toxicology & Legal Medicine* Vol. 17 No. 1 & 2, Jul-Dec 2014.
15. Babinski M.A., Rafael F.A., Steil A.D., Sousa Rodrigues C.F. High Prevalence of Sternal Foramen: Quantitative, anatomical analysis and its clinical implications in acupuncture practice. *Int J. Morphol* 2012;30(3):1042-1049.
16. *Anatomy Research International* Vol.2013 (2013) Article A D 780193 Relationship of sternal foramina to vital structures of the chest: A computed tomographic study.
17. Sternal Foramen- Medico-legal & Clinical Implications. *IJSR-International Journal of Scientific Research.* Vol: 5/issue3/March2016-ISSN NO2277-8179/IF:3.508/IC value:69.48.
18. Congenital Foramen in the body of sternum. Bermio V.S., Jos Hemlatha G.A. *International Journal of Anatomy and Research.* *Int Anat Res*2014, Vol. 2(3):545-548 ISSN2321-4287.
19. The sternal foramen: the possible forensic misinterpretation of an anatomic abnormality. Jitender Kumar Jakhar, Vijay Pal. *J Indian Acad Forensic Med.* July- Sep 2015, Vol.37, No.3 ISSN0971-0973.