

Content available at: <https://www.ipinnovative.com/open-access-journals>

Indian Journal of Forensic and Community Medicine

Journal homepage: <https://www.ijfcm.org/>**Case Report****Silent while living, speaks when dead- A case report of manual strangulation**Mohammed Ziyauddin G Saiyed^{b1*}, Chetan B Jani¹¹Dept. of Forensic Medicine and Toxicology, SAL Institute of Medical Sciences, Ahmedabad, Gujarat, India**ARTICLE INFO***Article history:*

Received 13-04-2024

Accepted 04-05-2024

Available online 15-07-2024

Keywords:

Delayed death

Finger nail abrasions

Multidisciplinary approach

Throttling

ABSTRACT

Victim of throttling in majority of the cases die instantaneously as the perpetrator continues to apply pressure till death ensues. In certain cases, victim may survive for some time if pressure is withdrawn due to any reason. In such cases, after the incident, he/she may not be conscious or able to speak for giving history; but the injuries produced by application of pressure by palms and fingers, if looked for them carefully, may speak by themselves about the incident. Presenting here, a case of 52 years old female, where the “made-up” history by the relatives misdirected the thinking process of the clinicians as the patient could not speak at all at the time of admission to the hospital until death. Autopsy conducted on 5th day of hospitalization revealed typical signs of the homicidal act the victim was subjected to, which could have been identified in the “fresh” stage at the time of admission and could have helped in some more detailed medico legal investigations if it could have been referred to Forensic Medicine experts of the institute. This case report stresses on the need of multi-disciplinary approach at the time of treatment of any patient with suspicious history, to have some different angle of view with regards to medico legal concerns and hence, it is discussed here.

This is an Open Access (OA) journal, and articles are distributed under the terms of the [Creative Commons Attribution-NonCommercial-ShareAlike 4.0 License](https://creativecommons.org/licenses/by-nc-sa/4.0/), which allows others to remix, tweak, and build upon the work non-commercially, as long as appropriate credit is given and the new creations are licensed under the identical terms.

For reprints contact: reprint@ipinnovative.com**1. Introduction**

Throttling is a mean of producing asphyxia by application of pressure on the neck with the palms & fingers of hands. Most commonly it is homicidal in nature. In majority of the cases death results almost immediately but, it may be delayed in some instances. Death may be delayed due to variety of causes as mentioned by various authors.^{1,2} In cases where victim survives for some time after the incident, he/she may not be conscious or able to speak for giving history, but the injuries produced by application of pressure by palms and fingers may speak by themselves about the incident, if examined carefully. Here is a case where, a 52 years old female was brought by the relatives in anxious state with difficulty in breathing & swallowing along with inability to speak and bilateral upper & lower

limb weakness. The only sign the clinicians could find was swelling in the neck and subcutaneous emphysema in neck and upper chest, but no injury was mentioned in clinical records. Medicolegal autopsy conducted on 5th day of hospitalization revealed important evidence of throttling in form of typical finger nail abrasions on both the sides of neck & deep muscle bruising, along with collapsed lungs on histopathology, which were suggestive of death as a result of complications of pressure over neck due to throttling. The injuries could have healed & no evidence even at autopsy could have been found regarding the offence when victim had survived for some more time and if unfortunately after that death had resulted. Meticulous autopsy played vital role in revealing the pathognomonic evidence, which was missed while patient was alive in the hospital. This case report stresses the need of multi-disciplinary approach at the time of treatment of the patient with suspicious history to have

* Corresponding author.

E-mail address: dr.ziya.saiyed@gmail.com (M. Z. G. Saiyed).

some different angle of view with regards to medico legal concerns.

2. Case Presentation

A 52 years old female was brought to the casualty of GCS hospital, Ahmedabad (previous workplace of authors) by her relatives in anxious state with complaints of difficulty in breathing & swallowing along with inability to speak and all four limbs weakness. Past history of cholecystectomy before 1 month was revealed. No any other history of any trauma was given by the chaperones. Patient was immediately attended by casualty medical officer and oxygen was started as oxygen saturation was 76%. After thorough clinical examination, clinicians could only find swelling in the neck region with subcutaneous emphysema in neck and upper chest & quadriplegia. No mark of any external injury was mentioned in the case papers. As the clinicians found the history to be suspicious, they asked the victim about the incident again and even with quadriplegia, almost after 16 hours of admission, she revealed that her son tried to throttle her by nodding her head in response to the leading questions asked by the doctors, as she could not speak. The diagnosis put was “? Strangulation” and medico legal case was issued.

Multi Slice Computed Tomography (MSCT) scan of cervical spine didn't show any definite erosion, sclerosis, fracture or collapse. MSCT scan of brain was normal. High Resolution Computed Tomography (HRCT) scan of thorax found bilateral pneumothorax (more on right side) - ? tension type, pneumomediastinum and bilateral subcutaneous emphysema. Inter-costal drainage tube was inserted on right side. Patient used to maintain oxygen saturation with supplemental oxygen during the course of treatment but, suddenly in the morning of 5th day of hospitalization, she started developing difficulty in respiration and bradycardia for which cardio-pulmonary resuscitation was started but it failed and patient died. The speech could not be revived till end. Medico legal autopsy was advised. Police in inquest mentioned that death occurred due to breathlessness as a result of some disease as they dint find any evidence of throttling in clinical records.

2.1. Autopsy findings

Autopsy was conducted on 5th day of hospitalization. External examination of neck showed abrasions with brownish scab (confirming the 5 days old abrasion)³ over following areas of the body.

Over left side of neck (Figure 1), (1) Linear, 2.5 x 0.1 cm sized, but in the lower half cm of its length, it was 0.4 cm wide, the upper end of which lied 6 cm below & 5 cm lateral to mid of chin, going obliquely downwards and laterally, (2) Crescent shaped with its convexity upwards & medially, 0.4 cm long, situated 3 cm below and 0.5 cm left to mid of chin, (3) Linear, 0.1 cm long, located 5.5 cm below & 4.8 cm

lateral to mid of chin.

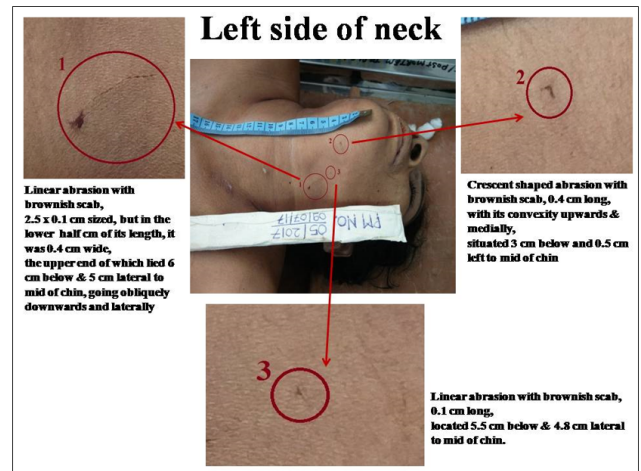


Figure 1: Injuries over left side of neck

Over right side of neck (Figure 2), (4) Linear, 0.5 cm long, situated 2 cm below & 4 cm lateral to mid of chin, oblique with upper end medially, going downwards and laterally, (5) 0.3x0.2 cm sized, situated 5.5 cm below & 5.5 cm lateral to mid of chin, (6) 0.1x0.1 cm sized, located 5.8 cm below & 8 cm lateral to mid of chin., A surgically stitched wound of inter-costal drainage was found on right lateral side of chest (therapeutic).

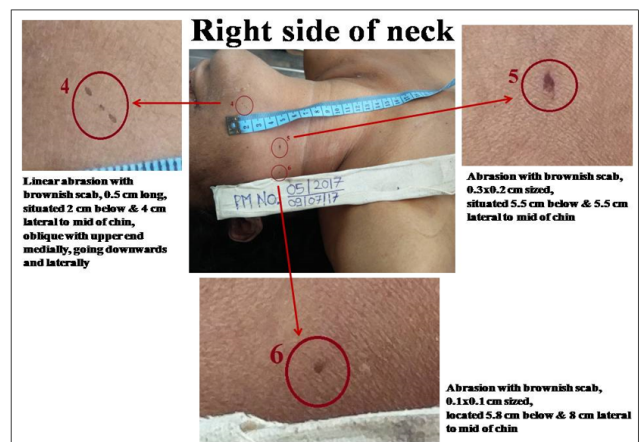


Figure 2: Injuries over right side of neck

Internal examination showed hematoma of 1 cm diameter in deep muscle of neck (Thyrohyoid) on left side (Figure 3), but no any fracture of hyoid bone, thyroid or any other cartilage or cervical vertebra. Both lungs were oedematous.

Histopathology showed oedema, congestion, emphysematous changes with evidence of collapse in both the lungs. Rest of the vital organs showed congestion while atheromatous changes were noted in aorta and coronaries.

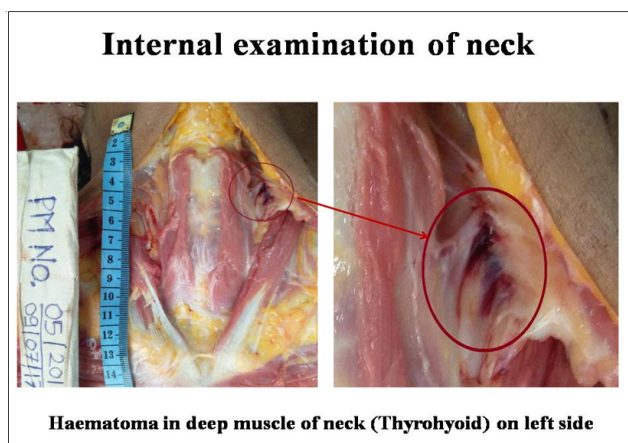


Figure 3: Internal examination of neck structures

Respiratory failure as a complication of pressure over neck due to throttling was concluded to be the cause of death.

3. Discussion

Delayed death in case of throttling is rare but not impossible. Evidence of injuries suffered by the victim as a result of throttling apart from the history forms a solid substance for framing the charge on the suspect. Absence of any external or internal injury although rare in throttling, can be there when victim is unconscious and amount of pressure to the neck is minimal but, generally some injury is always present.⁴ Two unique cases are reported by Sharma A et al., where the history was suggestive of some illness but actually they were revealed to be the cases of throttling associated with poisoning. Here, the external injuries resulting due to throttling in form of multiple abrasions, contusions were not noticed by the clinicians in a hustle to treat the patient, but were significantly noted during autopsy.⁵ In present case as well, even after the history of throttling was given by the victim by gestures after 16 hours of admission, clinicians failed to notice any external injury. We found typical signs of throttling at autopsy even on the 5th day of hospitalization, which could have been easily examined in fresh state and some more information regarding medico legal proceedings could have been derived if Forensic Medicine experts were called at the time of admission. Similarly, Badkur DS et al. have reported that they discovered typical fingernail abrasions on 7th day of hospitalization of a patient of attempted throttling and the same were confirmed on the 19th day when autopsy was performed.¹

Probable reasons for failing to note the injuries by Clinicians during treatment:

1. Clinicians are more focused on treatment aspect of management of the patient.

2. They face fewer encounters with such cases, as majority of the victims die instantaneously in case of throttling.
3. They have less orientation to medico legal concerns related to any case.
4. Advantages of noticing important injuries in fresh stage:
5. It can yield information more accurately, viz. time since injury, object causing such an injury, direction of force etc.⁶⁻⁸
6. It can give information to the Investigating officer (I.O.), which helps him in framing the charge for the offence.
7. The I.O. can arrange for recording Dying declaration, if felt necessary from the severity of the injuries and offence.

4. Conclusion

Multidisciplinary approach in the patients with suspicious history can be fruitful in medico legal cases. The system of referral of medico legal cases should be developed in tertiary care level hospitals where all the medico legal cases should be scrutinized with medico legal point of view by Forensic medicine experts while treatment of such patients is going on by the department concerned. This can help in collecting the valuable evidence related to the crime that can be lost if more time has elapsed after the incident. This evidence ultimately can be proved useful in future court proceedings.

5. Sources of Funding

None.


6. Conflict of Interest

None declared.

References

1. Badkur DS, Arorae A, Jain CS. Delayed death in case of attempted strangulation mechanism of cerebral thrombosis and infarction - a case report. *J Indian Acad Forensic Med.* 2005;27(4):263–5.
2. Paolo MD, Guidi B, Bruschini L, Vessio G, Domenici R, Ambrosino N. Unexpected delayed death after manual strangulation: need for careful examination in the emergency room. *Monaldi Arch Chest Dis.* 2009;71(3):132–4.
3. Mathiharan K, Patnail A, editors. *Modi's Medical Jurisprudence and Toxicology.* 23rd ed. Gurgaon, India: Lexis Nexis; 2010. p. 695.
4. Reddy KSN, Murty OP. *The essentials of Forensic Medicine and Toxicology.* 33rd ed. New Delhi: Jaypee Brothers; 2014. p. 353.
5. Sharma A, Sharma VK, Satpathy DK. It too happens: two unusual case studies. *J Indian Acad Forensic Med.* 2004;26(1):37–8.
6. Subrahmanyam BV. *Parikh's Textbook of Medical Jurisprudence, Forensic Medicine and Toxicology.* 9th ed. New Delhi: CBS Publishers & Distributors; 2023. p. 223.
7. Vij K. *Textbook of Forensic Medicine and Toxicology.* 5th ed. Gurgaon, India: Elsevier; 2011. p. 215.
8. Rao N. *Textbook of Forensic Medicine & Toxicology.* 2nd ed. New Delhi: Jaypee Brothers Medical Publishers; 2010. p. 223.

Author biography

Mohammed Ziyauddin G Saiyed, Professor  <https://orcid.org/0000-0003-2269-5870>

Chetan B Jani, Professor and Head

Cite this article: Saiyed MZG, Jani CB. Silent while living, speaks when dead- A case report of manual strangulation. *Indian J Forensic Community Med* 2024;11(2):70-73.