

Content available at: <https://www.ipinnovative.com/open-access-journals>

Indian Journal of Forensic and Community Medicine

Journal homepage: <https://www.ijfcm.org/>

Case Report

Pituitary neuroadenoma as an 'Incidentaloma' in a case of road traffic accident

Boddepalli Devaraj^{1*}, Kattamreddy Ananth Rupesh¹, Srinivasarao Vavilapalli², Jitendra Durga Kanna Allu¹

¹Dept. of Forensic Medicine and Toxicology, Andhra Medical College, Visakhapatnam, Andhra Pradesh, India

²Dept. of Pathology, Andhra Medical College, Visakhapatnam, Andhra Pradesh, India



ARTICLE INFO

Article history:

Received 13-04-2024

Accepted 02-05-2024

Available online 15-07-2024

Keywords:

Pituitary adenoma

Endocrine manifestations

Mental health disorders

Headache

Vision loss

ABSTRACT

Background: Pituitary adenomas are the most common tumors found in the Sella region. Functional pituitary adenomas exhibit a wide range of endocrine manifestations due to either hypo- or hyperfunction of the pituitary gland, as well as mass effect. They can have a slow but severe impact on vision due to compression of the optic nerves, optic chiasm and cavernous sinus.

Case Report: A 42-year-old male, a security guard at a local dabba, was struck by a van while crossing the road. He sustained a head injury and unfortunately passed away during treatment at our tertiary case institute. At autopsy, upon examination of the skull, a mass measuring 5x5x3cm was discovered in the suprasellar area of base of skull. This mass was sent for histopathological examination, which confirmed it to be a "Pituitary neuroendocrine tumor possibly gonadotropic in nature." However, the cause of death in this case was opined as 'Head injury'.

Discussion: Forensic pathologists rarely encounter intracranial neoplasms that present as sudden and unexpected deaths. The incidence of undiagnosed fatal brain tumors detected at autopsy has been reported to range between 0.02% and 0.4%. Several studies have investigated the relationship between hormonally active pituitary adenomas and both mental health disorders and quality of life. One study by Johnson et al. found that patients with nonfunctional adenomas reported impairments in physical and emotional well-being compared to the normal population. Headache and visual symptoms are most commonly associated with pituitary adenomas.

Conclusion: In the present case, although it was an incidental finding and not contributing to the cause of death, we cannot underestimate the effect of the tumor on the visual acuity of the decedent. Nonetheless, visual impairment due to the tumor could also have partially led to the road traffic accident.

This is an Open Access (OA) journal, and articles are distributed under the terms of the [Creative Commons Attribution-NonCommercial-ShareAlike 4.0 License](https://creativecommons.org/licenses/by-nc-sa/4.0/), which allows others to remix, tweak, and build upon the work non-commercially, as long as appropriate credit is given and the new creations are licensed under the identical terms.

For reprints contact: reprint@ipinnovative.com

1. Introduction

The pituitary gland is a pea-sized endocrine gland located at the base of the brain, resting upon the hypophyseal fossa of the sphenoid bone in the center of the middle cranial fossa. It sits within a protective bony enclosure called the Sella turcica, which is covered by the dural fold known as the diaphragma sellae. Pituitary adenomas are among

the most common intracranial tumours encountered in clinical practice with a prevalence of 115 cases per 100,000 population and approximately 1 new case per 100,000 population per year.¹ Adenomas smaller than 10mm are classified as microadenomas, while those larger than 10mm are termed macroadenomas.² While the majority of pituitary adenomas are hormonally active, 15–30% of pituitary adenomas are termed clinically non-functioning, meaning they are not associated with a functional tumour secreting excess adrenocorticotrophic hormone, growth

* Corresponding author.

E-mail address: devarajboddepalli@gmail.com (B. Devaraj).

hormone, prolactin, or thyroid stimulating hormone. Many clinically nonfunctioning pituitary adenomas may test positive for gonadotropin stains, but they don't directly release hormones to cause hormonal syndromes.³ They are therefore usually discovered during investigation of symptoms related to mass effect (i.e. headaches, visual changes) or, most commonly, as an incidental finding. The majority of microadenomas are incidentalomas, but in this case, it was a macroadenoma, which was incidentally found during an autopsy. The diagnosis is confirmed by testing hormonal levels and by radiographic imaging like CT, MRI of the pituitary. The preferred medical treatments for the condition typically encompass dopamine agonists, long-acting somatostatin analogs, and growth hormone receptor antagonists.⁴ When these therapies prove insufficient or in cases where tumor size or symptoms necessitate more direct intervention, transsphenoidal adenectomy emerges as the surgical treatment of choice. Additionally, radiation therapy may be employed as an adjunct or alternative method to manage the condition effectively.

2. Case Report

The incident pertains to a 42-year-old male security guard, employed at a local dhaba, who was involved in a road accident. He sustained a severe head injury after being struck by a van while crossing the road. The patient was admitted to our tertiary care centre with a Glasgow Coma Scale (GCS) score of E1V1M2. A poor prognosis was explained to the patient's family. Despite treatment efforts, the patient succumbed within a few hours. As is customary in such cases, his body underwent a forensic autopsy to ascertain the precise cause of death.

At autopsy, the scalp on reflection showed a diffuse contusion all over. The skull revealed a fissure fracture of size 20cm over the right occipitotemporal areas, extending into the right middle cranial fossa at the base of the skull. Diffuse subdural hemorrhage and subarachnoid hemorrhage were noted throughout the brain bilaterally, predominantly over the surface of the right cerebral hemisphere and the base of the left cerebral hemisphere in the anterior cranial fossa region. Further, the brain was intensely edematous.

A 5x5x3cm mass (Figure 1), weighing about 60gms, encapsulated within the pituitary gland with extension to the skull base in the Sella region (Figure 2). This mass was sent for histopathological examination, which confirmed it to be a "Pituitary neuroendocrine tumor, possibly gonadotropic in nature." (Figure 3). The cause of death in that case was opined as 'Head Injury' owing to the presence of diffuse subdural and subarachnoid hemorrhage all over the brain bilaterally.

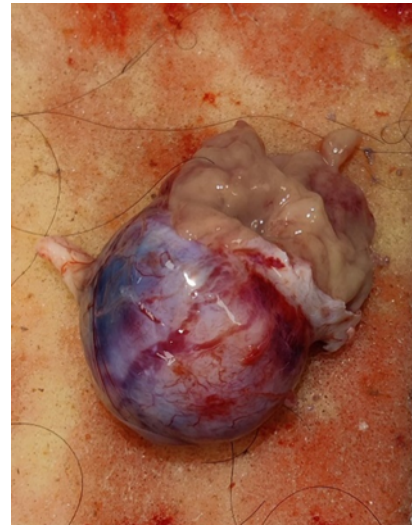

Figure 1: Gross appearance of pituitary projecting from macroadenoma at autopsy

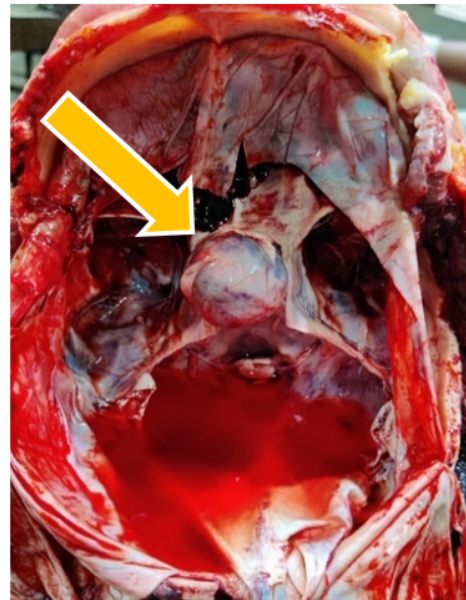


Figure 2: Encapsulated mass Sella Terica in the base of skull

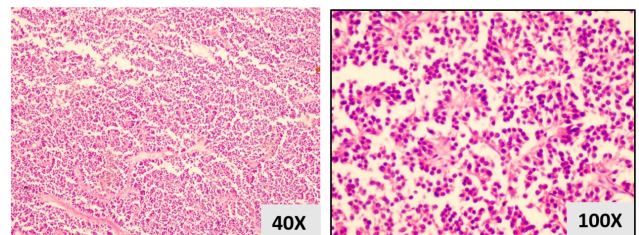


Figure 3: Histological view of the pituitary tumor composed of small, uniform polygonal cells disposed in sheets and cords that were focally acutely infarcted with hyper eosinophilic "ghost cells" and early infiltrates of neutrophils (H&E, 40X, 100X)

3. Discussion

This is a case of road traffic accident in which the cause of death was “Head Injury” and the pituitary adenoma was an incidental finding during autopsy. Pituitary adenomas may be classified as non-functional and functional. Non-functional adenomas are benign tumors and are usually not associated with clinical evidence of hormonal changes. On the other hand, functional adenomas exhibit a wide range of endocrine manifestations due to either hypo or hyperfunction of the pituitary gland. They may affect one or more hormones/hormonal systems, commonly involved are growth hormone and prolactin, leading to unexpected bone expansion and lactation in both males and females.⁵ Non-functioning pituitary adenoma (NFPA) is a major source of visual disorders, and is diagnosed later than functioning adenoma, often with larger tumor volume. Incidence of NFPA was 28–33.2% in pituitary adenoma populations, with or without visual involvement but 58% in case of pituitary adenoma specifically with visual involvement.⁶ These adenomas can also have a slow but severe impact on vision, causing bitemporal hemianopsia (interfering with peripheral vision) due to compression of the optic nerves or chiasma. Moreover, increased intracranial pressure often results in severe headaches. Additionally, various psychiatric manifestations such as depression, anxiety, and emotional instability may be noted in a few patients.

Pituitary tumor apoplexy refers to a clinical syndrome precipitated by the expansion of a pituitary adenoma by hemorrhage or infarction due to the expansion of the Sella turcica. Delayed diagnosis, mismanagement, and misdiagnosis of this condition can result in either permanent physical impairment or death.⁷ While sudden death following pituitary tumor apoplexy is rarely reported, postmortem examinations showed hemorrhage and necrosis of pituitary adenoma in few instances.

Pituitary adenomas can indeed have significant effects on individuals’ health and well-being due to their potential to disrupt hormone production, compress surrounding structures in the brain, and cause a wide range of distressing symptoms. However, it is important to clarify that while hemorrhage within a preexisting pituitary tumor can lead to acute complications such as sudden-onset severe headache, visual disturbances, or hormonal imbalances, sudden death solely due to hemorrhage in a pituitary tumor is relatively rare.¹

Patients with pituitary tumors were more likely to be diagnosed with a MHD, approximately 15% were diagnosed with a MHD within 1 year of their diagnosis. Independent risk factors included female gender and substance abuse.⁸

Within the medico-legal framework, manifestations such as peripheral vision impairment, headaches, behavioural alterations, and sudden demise attributed to pituitary apoplexy merit notable consideration. Hence, it is important

to recognize and appropriately manage these tumors to minimize their impact on patients.

4. Conclusion

In this instance, a pituitary adenoma was fortuitously identified during postmortem examination, manifesting as a stage III adenoma. Stage III adenomas are typically characterized by macroadenomas, which exhibit enlargement and infiltration of the floor of the Sella turcica or extension into the suprasellar region. Surprisingly, despite it being a macroadenoma, it is notable that the deceased did not exhibit any signs or symptoms. Although it is an incidental finding and not contributing to the cause of death, we cannot underestimate the effect of the tumour on the visual acuity of the decedent. In the present case, visual impairment due to the tumour could also have partially led to the road traffic accident.

5. Sources of Funding

None.

6. Conflict of Interest

None to declare.


Acknowledgements


We extend our sincere appreciation to the Department of Pathology at Andhra Medical College, for their invaluable support in this case. Our gratitude also goes to Professor & Head of the Department of Forensic Medicine & Toxicology, Dr. K. Mamatha, along with other faculty members and postgraduates for their unwavering assistance and support.

References


- Shields LBE, Balko MG, Hunsaker JC. Sudden and unexpected death from pituitary tumor apoplexy. *J Forensic Sci.* 2012;57(1):262–6.
- Asa SL, Ezzat S. The cytogenesis and pathogenesis of pituitary adenomas. *Endocr Rev.* 1998;19(6):798–827.
- Pituitary Tumors Treatment (PDQ®)—Health Professional Version. Available from: <https://www.cancer.gov/types/pituitary/hp/pituitary-treatment-pdq>.
- Tritos NA, Miller KK. Diagnosis and management of pituitary adenomas: A review. *JAMA.* 2023;329(16):1386–98.
- Melmed S. Pituitary-tumor endocrinopathies. *N Engl J Med [Internet].* 2020;382(10):937–50.
- Abouaf L, Vighetto A, Lebas M. Neuro-ophthalmologic exploration in non-functioning pituitary adenoma. *Ann Endocrinol (Paris).* 2015;76(3):210–9.
- Chanson P, Raverot G, Castinetti F, Cortet-Rudelli C, Galland F, Salenave S. Management of clinically non-functioning pituitary adenoma. *Ann Endocrinol (Paris).* 2015;76(3):239–47.
- Maurer R, McNutt S, Daggubati LC, Ba DM, Liu G, Leslie D, et al. Mental health disorders in newly diagnosed non-functional pituitary adenoma under initial observation: an observational cohort study using the nationwide MarketScan database. *Pituitary.* 2022;25(1):85–91.

Author biography

Boddepalli Devaraj, Resident  <https://orcid.org/0009-0000-1408-9825>

Kattamreddy Ananth Rupesh, Assistant Professor  <https://orcid.org/0000-0003-1525-3740>

Srinivasarao Vavilapalli, Assistant Professor

Jitendra Durga Kanna Allu, Resident  <https://orcid.org/0009-0004-6607-6689>

Cite this article: Devaraj B, Rupesh KA, Vavilapalli S, Allu JDK. Pituitary neuroadenoma as an 'Incidentaloma' in a case of road traffic accident. *Indian J Forensic Community Med* 2024;11(2):66-69.